



# The Open Dentistry Journal

Content list available at: <https://opendentistryjournal.com>



## RESEARCH ARTICLE

### Mandibular Behavior after Rapid Maxillary Expansion: A Clinical Study

Radwan A. Haffaf<sup>1,\*</sup> , Abdul-kareem Hasan<sup>1</sup> and Mohammad Tizini<sup>1</sup>

<sup>1</sup>Department of Orthodontics, Faculty of Dentistry, Tishreen University, Lattakia, Syrian Arab Republic.

#### Abstract:

#### Background:

Rapid Maxillary Expansion (RME) is a primary part of the contemporary orthodontic treatment plans. In addition to the maxilla, it is important to know its effect on the other dentofacial components. Some studies showed dentofacial changes after RME in the sagittal and vertical planes. The clinical importance of these changes is controversial.

#### Objective:

To investigate the mandibular changes after RME as the only treatment intervention in the sagittal and vertical planes.

#### Methods:

Twenty-eight growing patients aged 4-14 years were included in the current study. The bonded acrylic splint expander was used. Lateral cephalometric radiographs were taken at the beginning of the treatment (T1) and after a retention phase of six months (T2). The mandibular changes were assessed using vertical parameters (SN.MP, MMA, LAFH/TAFH, S.AR/AR.GO) and sagittal parameters (SNB, S.N.POG, N.A.POG). The changes between T1 and T2 were examined by paired samples T-test.

#### Results:

Two parameters showed a backward rotation in the vertical plane. The parameter S.AR/AR.GO showed a significant increase. The skeletal convexity increased with no clinical significance.

#### Conclusion:

There were statistically significant changes in the sagittal and vertical planes with no clinical importance. RME may affect the mandibular condyle position.

**Keywords:** Rapid maxillary expansion, Hyrax expander, Mandibular changes, Clinical study, Growth period, Maxillary deficiency.

#### Article History

Received: August 28, 2019

Revised: October 30, 2019

Accepted: December 18, 2019

## 1. INTRODUCTION

Rapid Maxillary Expansion (RME) is a routinely used orthopedic treatment for many clinical conditions [1 - 3]. The earliest published paper was written by E.C. Angell (the father of rapid maxillary expansion) [4]. After the reintroduction of this procedure by Haas, RME has been commonly used in the field of orthodontics [5, 6]. Several appliances have been introduced with new modifications in the expander or the appliance design. The bonded acrylic splint expander, transverse sagittal maxillary expander (TSME) [7],

Ragno expander [8], the memory screw [9, 10], and the differential maxillary expander [11], have new mechanisms of action. Some concerns have been raised regarding the oral hygiene and food control in patients wearing orthodontic appliances [12], especially in patients with restorations [13, 14] or those with incorrect behavior [15]. However, some types of expanders are considered more hygienic than others [16].

Many studies investigated different aspects of the RME procedure. Some studies were histological [17]. Others investigated the relapse [18], stability [19] and the side effects related to RME [20].

Increasing the Vertical Dimension (VD) after the maxillary expansion is a primary consideration in treatment planning [21]. Some authors did not find any statistically significant

\* Address correspondence to this author at the Department of orthodontics, Faculty of Dentistry, Tishreen University, Lattakia, Syrian Arab Republic;  
E- mail: [radwan.haffaf@yahoo.com](mailto:radwan.haffaf@yahoo.com)

increase [22]. Others claimed that there was a statistically significant increase without any clinical importance [21]. Lineberger stated that the VD increasing had no prejudicial effects on the vertical skeletal relationships. According to long term studies, it was a transient effect [23].

A maxillary displacement after RME has been reported [24]. Mandibular displacement is more controversial, keeping in mind that the mandible is the dynamic part of the dentofacial structures. Some authors reported an anterior mandibular displacement, which improved class II malocclusion, either through dental casts studies [25] or by cephalometric evaluation [20]. The “foot and shoe” theory and the “spontaneous correction of class II malocclusion” phenomenon were introduced [26]. In fact, these had been pointed in the German literature since the early 1900s by korbitz [26, 27]. However, the mandibular backward rotation induced by the maxillary expansion has been described [28].

Despite the large number of clinical studies that investigated the effects of RME, there is a lack of information regarding patients treated by RME as the only treatment intervention. The aim of this study was to investigate the mandibular sagittal and vertical changes subsequent to rapid maxillary expansion.

## 2. MATERIALS AND METHODS

The lateral cephalograms used in this study were obtained from a previous thesis and no patient was treated, especially for this article. The sample consisted of twenty-eight patients (16 males and 12 females) with indications for transverse expansion aged 4-14 years [ $9 \pm 1.12$ ], and without needing any mandibular intervention during the activation and retention periods. To determine the sample size, G\*Power 3.1 (Heinrich-Heine-Universität, Dusseldorf, Germany) program was used based on the results of a similar previous study [29]. Including a control group was unfeasible due to ethical reasons. It is unethical not to intervene when a diagnosed transverse discrepancy is present [30].

The inclusion criteria were:

- Maxillary constriction.
- Posterior crossbites.
- Class III face mask therapy [phase one].
- Functional therapy of class II [phase one].

Exclusion criteria were:

- Previous orthodontic treatment.
- Syndromes or congenital disorders.
- Class II division two.
- Asymmetries in another plane.
- Need for mandibular orthodontic intervention.

This study was conducted according to the world medical association (WMA) guidelines (Fortaleza, Brazil, October 2013). Patient health and safety were the primary considerations [31]. Informed consents were performed. Lateral cephalometric radiographs (Cranex<sup>®</sup> Excel Ceph, Soredex, Tuusula, Finland) were taken before treatment (T1). The appliance design was similar to McNamara design (bonded rapid

maxillary expander with occlusal acrylic coverage), as shown in Fig. (1). Hyrax<sup>®</sup> expander (Dentaurum, Pforzheim, Germany) was used. The expander was activated one turn per day until the palatal maxillary cusps reach the buccal mandibular cusps. Overcorrection of 2-3 millimeters was gained. The overcorrection was visually estimated. The appliance was left in place during the retention phase. The average retention period ranged from 164 to 192 days ( $178 \pm 7$ ). After the retention phase, lateral cephalograms were taken (T2).

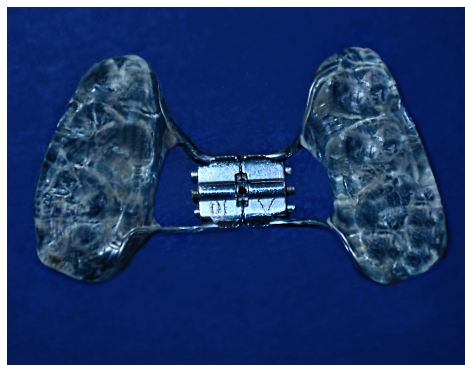


Fig. (1). The bonded hyrax appliance

### 2.1. Cephalometric Analysis

Lateral cephalograms were exported as DICOM (Digital Imaging and Communications in Medicine) files. They were digitized using Facad cephalometric software (Ilexis AB, Sweden) installed on x64-based PC (Hewlett-Packard, Palo Alto, California, USA) running the windows 10 professional edition (Microsoft, Redmond, Wash). Five cephalograms were digitized in every session. Frankfort plane was rotated to be horizontal before landmarks identification. The auto-contrast function was used for almost every point detection. The vertical assessment was based on: SN-MP, MMA, LAFH /TAFH, S.AR/AR.GO. The sagittal assessment was based on: SNB, S.N.POG, N.A.POG. Ten cephalograms were digitized one month later to test the intraoperator reliability. Table 1 shows the definition of the used landmarks.

The variables shown in Fig. (2) (The vertical parameters) and Fig. (3) (The sagittal parameters) were defined as follows:

- SN.MP: The angle formed between the anterior cranial base [S.N] and the mandibular plane [line between menton and constructed Gonion].
- MMA: The angle formed between the nasal line [ANS, PNS] and the mandibular plane [ME. GO].
- LAFH: The vertical distance from Menton to the anterior nasal spine.
- TAFH: The vertical distance from Menton to Nasion.
- S.AR/AR.GO: The ratio between the posterior cranial base [represented as a line from S to AR] and the height of mandibular ramus [a line from AR to constructed gonion]
- SNB angle: Angle formed by points S, N and B
- S.N.Pog angle: Angle formed by points S, N and Pogonion
- N.A.Pog angle: Angle formed by points N, A and pogonion

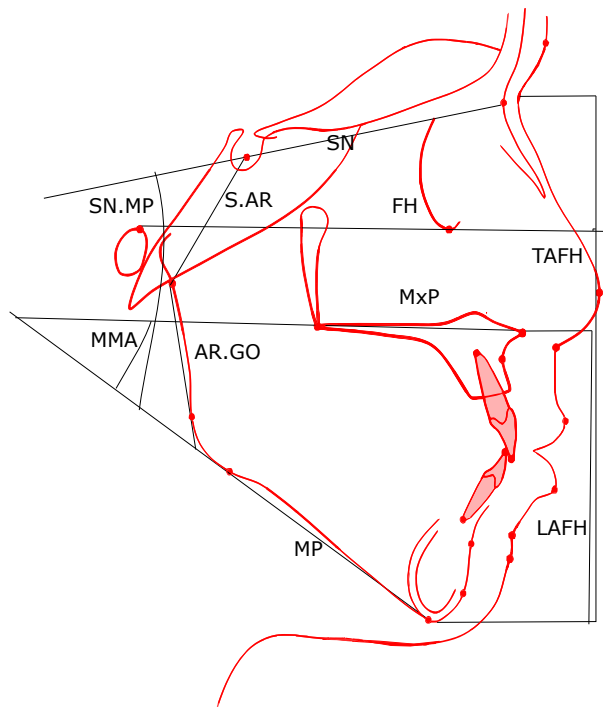


Fig. (2). The vertical parameters.

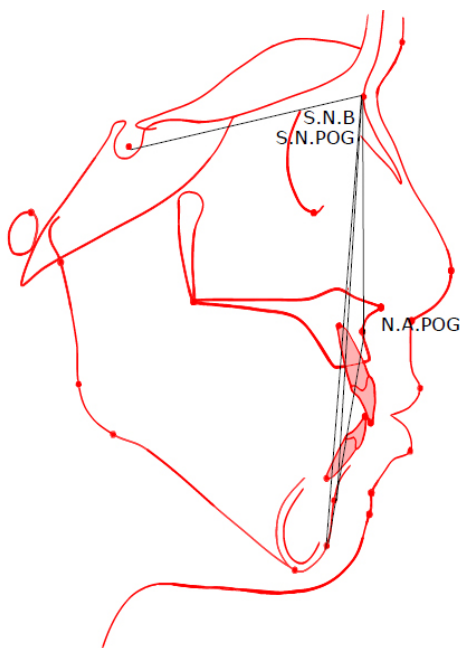

Fig. (3). The sagittal parameters.

Table 1. Definition of landmarks.

Landmarks	Definition
Sella (S)	The center of sella turcica
Nasion (N)	The most anterior point on the frontonasal suture
Menton (ME)	The most inferior point on the symphyseal outline
Pogonion (POG)	The most anterior point on the mandibular symphysis
Anterior nasal spine (ANS)	Tip of the anterior nasal spine

(Table 1) contd.....

Landmarks	Definition
Posterior nasal spine (PNS)	The tip of the posterior nasal spine
Orbitale (OR)	The most inferior point on the lower border of the bony orbit
Porion (P)	The most superior point on the outline of the external auditory meatus
Constructed Gonion (GO)	The intersection of the mandibular plane with a plane through Articulare, Posterior and along the portion of the mandibular ramus inferior to it
A point (A)	The deepest point of the curve of the maxilla between the anterior nasal spine and the dental alveolus
B point (B)	the deepest point on the bony curvature between the crest of the alveolus and pogonion
Articulare (AR)	The point of intersection between the posterior border of the mandibular condyle and the lower border of the cranial base

2.2. Statistical Analysis:

Intraoperator reliability was examined by the correlation coefficient test. In addition, the Bland-Altman method was used. Treatment changes were examined by paired samples t-tests. Statistical significance was tested at  $P < .05$ . Table 2 shows descriptive statistics for the measurements before and after treatment, and the results of paired samples t-tests. Microsoft Office / Excel 2016 (Microsoft, Redmond, Wash) was used for statistical analysis.

3. RESULTS

The intraoperator error was limited (average correlation results:  $r=0.98$ ). As an example, Fig. (4) shows all the repeated measurements of the variable SN. MP is between the upper and lower limit of agreement, which validates the tracing method. The null hypothesis was rejected for three vertical parameters and one sagittal parameter. Descriptive statistics and treatment changes for the cephalometric variables derived before and after orthodontic treatment are shown in Table 2

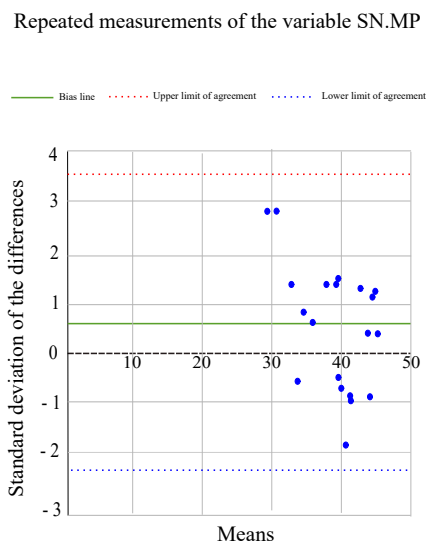


Fig. (4). Bland - altman plot, all the repeated measurements are between the ULA and LLA.

Table 2. Descriptive statistics and Treatment Changes.

		Pretreatment				Posttreatment					
Vertical	unit	MEANS	SD	MIN	MAX	MEANS	SD	MIN	MAX	DF	P VALUE
SN-MP	deg	38.85	5.09	28.3	44.5	39.51	3.96	32.2	44.8	0.66	*
MMA	deg	29.79	6.33	20.8	39.2	30.69	6.28	21.1	37.8	0.9	**
LAFH/TAFH	%	55.45	1.59	52.3	58	55.58	1.77	52.1	58.2	0.13	NS
S.AR/AR.GO	%	83.46	7.90	73.8	98.3	87.23	13.49	71.7	113	3.77	*
<b>Sagittal</b>											
SNB	deg	75.33	4.05	70.8	85	75.27	3.20	71.2	81.3	- 0.06	NS
S.N.POG	deg	75.69	4.18	70.7	85.8	75.63	3.26	71.9	81.9	- 0.06	NS
N.A.POG	deg	3.24	6.33	-7.7	13.8	4.4	5.65	-6.7	11.8	1.16	*

SD: standard deviation. N: number. MIN: minimum MAX: maximum. DF: difference. \* P value < 0.05, \*\* P value < 0.01, NS: not significant.

### 3.1. Vertical Assessment

SN-MP angle increased significantly from T1 to T2 (0.66 degree,  $p < 0,05$ ), and Maxillomandibular Angle (MMA) increased a mean of 0.9 degree ( $p < 0,05$ ). These increases had no statistical effect ( $p > 0,05$ ) on the ratio of lower anterior facial height to the total anterior facial height (LAFH/TAFH). S.AR/AR.GO increased significantly (3.77%,  $p < 0,05$ ).

### 3.2. Sagittal Assessment

SNB and S.N.POG changes were not statistically significant ( $p > 0,05$ ). N.A.POG showed a mean increase of 1.16 degrees ( $p < 0,05$ ).

## 4. DISCUSSION

The aim of the present study was to investigate the mandibular changes in the sagittal and vertical planes after RME as the only treatment intervention. RME was performed using the bonded acrylic splint expander.

One of the limitations of this study was the absence of a control group. The maxillary transverse deficiency is not a self-corrected malocclusion. It is not ethical to leave patients with maxillary deficiency without intervention. Pandis also considered the use of historical control groups problematic [32]. Another limitation was the unbalanced population (16 males *versus* 12 females), caused by the additional criterion used in the present study (the absence of necessity for mandibular intervention). This criterion decreased the number of patients available for the present study. It was challenging to find patients who need only maxillary orthodontic intervention during the first six months of the treatment period. However, the unbalanced population would not affect the biomechanical behavior of the mandible after maxillary expansion because it is not fully controlled by hormones. For the same reason, it was unfeasible to divide the patients into groups according to each type of malocclusion, or to increase the sample size.

Schudy emphasized that increasing the VD may exacerbate the sagittal discrepancy [33]. Almost every orthodontic malrelationship has a vertical, sagittal and transverse component [21]. The present study results showed a mandibular clockwise rotation and a bite opening effect after RME. As MMA increased significantly ( $p < 0,05$ ), it could be concluded that the clockwise rotation resulted from the dentoalveolar changes rather than the maxillary vertical displacement, which might affect the ratio of LAFH/TAFH. The LAFH/TAFH showed no significant changes after RME ( $p > 0,05$ ). The dentoalveolar changes could be like a flexion of the alveolar ridges [34], in addition to the tipping and extrusion of the anchor teeth [35, 36]. These changes could be compensated in the next stage if the patient had to go through a fixed appliance phase of treatment. This could be accomplished through the modification of the maxillary posterior teeth torque. However, the present study results were favorable because if the maxillary vertical displacement was responsible for the clockwise rotation, it should be controlled through extraoral appliances (like vertical pull chin cap), as suggested earlier [37]. Furthermore, this could be the reason for controversy between short term and long term clinical studies. The short term studies recorded VD increases after RME [24]. The long term studies

suggested that the VD increase was transient and had no long term deleterious effect [23]. The long term study, because of duration, would include a second phase of fixed appliances therapy with many variables to control; like the torque and prescription of posterior teeth brackets. The short term study may include a phase of fixed appliances therapy and may not.

The significant increase in S.AR/AR.GO ( $p < 0,05$ ) was caused either by S.AR increase or by AR.GO decrease. AR.GO decrease could be a result of condylar repositioning into a more upper or centric position. This may be produced by the elimination of the deviating contacts after expansion. The increase in S.AR could be induced if the expansion affected the spheno-occipital synchondrosis as suggested by some authors [38]. However, the lateral cephalometric radiographs are insufficient to evaluate the RME effect on the mandibular condyle position in its fossa. Further investigations are needed using other methods like Magnetic Resonance Imaging (MRI) and Cone Beam Computed Tomography (CBCT).

There was no mandibular displacement in the sagittal plane. However, there was a clockwise rotation which could camouflage any forward repositioning. The angle of convexity increased a mean of 1.16 degree ( $p < 0,05$ ), which could be resulted from the mandible clockwise rotation or the advancement of point A. Haas reported a forward displacement of point A after RME [6]. However, this convexity increase (1.16 degrees) in the growing patients could be compensated by the continuous growth of the mandible. Pancherz reported a late skeletal growth after the age of twenty [39].

## CONCLUSION

Within the limitation of this study, the results indicate:

- There was a clockwise rotation of the mandible and a bite opening effect after rapid maxillary expansion.
- The skeletal convexity increased after RME.
- Mandibular clockwise rotation and increased skeletal convexity are not contraindications for rapid maxillary expansion.
- RME may affect the condyle position and the posterior cranial base.

## LIST OF ABBREVIATIONS

<b>RME</b>	= Rapid Maxillary Expansion
<b>VD</b>	= Vertical Dimension
<b>MRI</b>	= Magnetic Resonance Imaging
<b>CBCT</b>	= Cone Beam Computed Tomography
<b>DICOM</b>	= Digital Imaging and Communications in Medicine
<b>WMA</b>	= World Medical Association

## ETHICAL APPROVAL AND CONSENT TO PARTICIPATE

The Study Was Approved by The Institutional Review Board of Tishreen University, Syrian Arab Republic Under Approval No.1143.

**HUMAN AND ANIMAL RIGHTS**

Not applicable.

**CONSENT FOR PUBLICATION**

Informed consents were performed.

**AVAILABILITY OF DATA AND MATERIALS**

The data supporting the findings of the article is available in the Department of Orthodontics, Faculty of Dentistry, Tishreen University, Lattakia, Syrian Arab Republic [www.tishreen.edu.sy].

**FUNDING**

None.

**CONFLICT OF INTEREST**

The authors declare no conflict of interest, financial or otherwise.

**ACKNOWLEDGEMENTS**

The authors acknowledge Dr. Hasan Ali (MSc. in Pediatric Dentistry) for the aid in study design, and Dr. Majed Amran (MSc. in Endodontics) for the aid in manuscript revision.

**REFERENCES**

- [1] McNamara JA Jr, Franchi L, McClatchey LM. Orthodontic and orthopedic expansion of the transverse dimension: A four decade perspective. *Semin Orthod* 2019; 25: 3-15. [http://dx.doi.org/10.1053/j.sodo.2019.02.002]
- [2] McNamara JA Jr, Lione R, Franchi L, *et al.* The role of rapid maxillary expansion in the promotion of oral and general health. *Prog Orthod* 2015; 16: 33. [http://dx.doi.org/10.1186/s40510-015-0105-x] [PMID: 26446931]
- [3] Moawad SG, Bouserhal J, Al-Munajed MK. Assessment of the efficiency of Erbium-YAG laser as an assistant method to rapid maxillary expansion: An *in vivo* study. *Int Orthod* 2016; 14(4): 462-75. [http://dx.doi.org/10.1016/j.ortho.2016.10.015] [PMID: 27856377]
- [4] Angell EC. Treatment of irregularities of the permanent adult teeth. *Dental Cosmos* 1860; 1: 540-4.
- [5] Haas AJ. The treatment of maxillary deficiency by opening the midpalatal suture. *Angle Orthod* 1965; 35(3): 200-17. [PMID: 14331020]
- [6] Haas AJ. Rapid expansion of the maxillary dental arch and nasal cavity by opening the midpalatal suture. *Angle Orthod* 1961; 31(2): 73-90.
- [7] Maspero C, Galbiati G, Giannini L, Farronato G. Sagittal and vertical effects of transverse sagittal maxillary expander (TSME) in three different malocclusion groups. *Prog Orthod* 2015; 16(25): 6. [http://dx.doi.org/10.1186/s40510-015-0075-z] [PMID: 25907431]
- [8] Çörekçi B, Göyenci YB. Dentofacial changes from fan-type rapid maxillary expansion vs traditional rapid maxillary expansion in early mixed dentition. *Angle Orthod* 2013; 83(5): 842-50. [http://dx.doi.org/10.2319/103112-837.1] [PMID: 23387338]
- [9] Wichelhaus A, Geserick M, Ball J. A new nickel titanium rapid maxillary expansion screw. *J Clin Orthod* 2004; 38(12): 677-80. [PMID: 15665443]
- [10] Halicioğlu K, Kiliç N, Yavuz İ, Aktan B. Effects of rapid maxillary expansion with a memory palatal split screw on the morphology of the maxillary dental arch and nasal airway resistance. *Eur J Orthod* 2010; 32(6): 716-20. [http://dx.doi.org/10.1093/ejo/cjp164] [PMID: 20403958]
- [11] Garib D, Flores-Mir C, Normando D, Janson G, Miguel JA, Lindauer S. An interview with Daniela Garib. *Dental Press J Orthod* 2019; 24(1): 16-26. [http://dx.doi.org/10.1590/2177-6709.24.1.016-026.int] [PMID: 30916245]
- [12] Pithon MM, Dos Santos MJ, Andrade CS, *et al.* Effectiveness of varnish with CPP-ACP in prevention of caries lesions around orthodontic brackets: An OCT evaluation. *Eur J Orthod* 2015; 37(2): 177-82. [http://dx.doi.org/10.1093/ejo/cju031] [PMID: 24997026]
- [13] Poggio C, Chiesa M, Scribante A, Mekler J, Colombo M. Microleakage in class II composite restorations with margins below the CEJ: *In vitro* evaluation of different restorative techniques. *Med Oral Patol Oral Cir Bucal* 2013; 18(5): e793-8. [http://dx.doi.org/10.4317/medoral.18344] [PMID: 23722121]
- [14] dos Santos RL, Pithon MM, Vaitsman DS, Araújo MT, de Souza MM, Nojima MG. Long-term fluoride release from resin-reinforced orthodontic cements following recharge with fluoride solution. *Braz Dent J* 2010; 21(2): 98-103. [http://dx.doi.org/10.1590/S0103-64402010000200002] [PMID: 20640354]
- [15] Poggio C, Dagna A, Chiesa M, Colombo M, Scribante A. Surface roughness of flowable resin composites eroded by acidic and alcoholic drinks. *J Conserv Dent* 2012; 15(2): 137-40. [http://dx.doi.org/10.4103/0972-0707.94581] [PMID: 22557811]
- [16] Ortu E, Sgolastra F, Barone A, Gatto R, Marzo G, Monaco A. Salivary *Streptococcus Mutans* and *Lactobacillus* spp. levels in patients during rapid palatal expansion. *Eur J Paediatr Dent* 2014; 15(3): 271-4. [PMID: 25306143]
- [17] Melsen B. Palatal growth studied on human autopsy material. A histologic microradiographic study. *Am J Orthod* 1975; 68(1): 42-54. [http://dx.doi.org/10.1016/0002-9416(75)90158-X] [PMID: 1056143]
- [18] Gurel HG, Memili B, Erkan M, Sukurica Y. Long-term effects of rapid maxillary expansion followed by fixed appliances. *Angle Orthod* 2010; 80(1): 5-9. [http://dx.doi.org/10.2319/011209-22.1] [PMID: 19852633]
- [19] Costa JG, Galindo TM, Mattos CT, Cury-Saramago AA. Retention period after treatment of posterior crossbite with maxillary expansion: A systematic review. *Dental Press J Orthod* 2017; 22(2): 35-44. [http://dx.doi.org/10.1590/2177-6709.22.2.035-044.oar] [PMID: 28658354]
- [20] Guest SS, McNamara JA Jr, Baccetti T, Franchi L. Improving Class II malocclusion as a side-effect of rapid maxillary expansion: A prospective clinical study. *Am J Orthod Dentofacial Orthop* 2010; 138(5): 582-91. [http://dx.doi.org/10.1016/j.ajodo.2008.12.026] [PMID: 21055598]
- [21] Chang JY, McNamara JA Jr, Herberger TA. A longitudinal study of skeletal side effects induced by rapid maxillary expansion. *Am J Orthod Dentofacial Orthop* 1997; 112(3): 330-7. [http://dx.doi.org/10.1016/S0889-5406(97)70264-6] [PMID: 9294364]
- [22] Wendling LK, McNamara JA Jr, Franchi L, Baccetti T. A prospective study of the short-term treatment effects of the acrylic-splint rapid maxillary expander combined with the lower Schwarz appliance. *Angle Orthod* 2005; 75(1): 7-14. [PMID: 15747809]
- [23] Lineberger MW, McNamara JA Jr, Baccetti T, Herberger T, Franchi L. Effects of rapid maxillary expansion in hyperdivergent patients. *Am J Orthod Dentofacial Orthop* 2012; 142(1): 60-9. [http://dx.doi.org/10.1016/j.ajodo.2012.02.019] [PMID: 22748991]
- [24] Davis WM, Kronman JH. Anatomical changes induced by splitting of the midpalatal suture. *Angle Orthod* 1969; 39(2): 126-32. [PMID: 5252050]
- [25] McNamara JA Jr, Sigler LM, Franchi L, Guest SS, Baccetti T. Changes in occlusal relationships in mixed dentition patients treated with rapid maxillary expansion. A prospective clinical study. *Angle Orthod* 2010; 80(2): 230-8. [http://dx.doi.org/10.2319/040309-192.1] [PMID: 19905846]
- [26] An interview with James A. McNamara Jr. *Dental Press J Orthod* [Internet] 2011; 16(3): 32-53. http://www.scielo.br/scielo.php?script=sci\_arttext&pid=S2176-94512011000300004&lng=en. [http://dx.doi.org/10.1590/S2176-94512011000300004]
- [27] Körbitz A. *Kursus der systematischen Orthodontik Ein Leitfadens für Studium und Praxis*. 2<sup>nd</sup> ed. Leipzig: Hans Licht 1914.
- [28] da Silva Filho OG, Boas MC, Capelozza Filho L. Rapid maxillary expansion in the primary and mixed dentitions: a cephalometric evaluation. *Am J Orthod Dentofacial Orthop* 1991; 100(2): 171-9. [http://dx.doi.org/10.1016/S0889-5406(05)81524-0] [PMID: 1867168]
- [29] Conroy-Piskai C, Galang-Boquieren MTS, Obrez A, *et al.* Assessment of vertical changes during maxillary expansion using quad helix or bonded rapid maxillary expander. *Angle Orthod* 2016; 86(6): 925-33. [http://dx.doi.org/10.2319/112315-799] [PMID: 27182780]
- [30] Baratieri C, Alves M Jr, Bolognese AM, Nojima MCG, Nojima LI. Changes in skeletal and dental relationship in Class II Division I

- malocclusion after rapid maxillary expansion: A prospective study. *Dental Press J Orthod* 2014; 19(3): 75-81. [http://dx.doi.org/10.1590/2176-9451.19.3.075-081.oar] [PMID: 25162569]
- [31] World Medical Association Declaration of Helsinki, Ethical Principles for Medical Research Involving Human Subjects. 64 WMA General Assembly. Fortaleza Brazil 2013.
- [32] Pandis N. Use of controls in clinical trials. *Am J Orthod Dentofacial Orthop* 2012; 141(2): 250-1. [http://dx.doi.org/10.1016/j.ajodo.2011.10.018] [PMID: 22284295]
- [33] Schudy FF. Vertical growth versus anteroposterior growth as related to function and treatment. *Angle Orthod* 1964; 34(2): 75-93.
- [34] Brunetto M, Andriani JdaS, Ribeiro GL, Locks A, Correa M, Correa LR. Three-dimensional assessment of buccal alveolar bone after rapid and slow maxillary expansion: A clinical trial study. *Am J Orthod Dentofacial Orthop* 2013; 143(5): 633-44. [http://dx.doi.org/10.1016/j.ajodo.2012.12.008] [PMID: 23631965]
- [35] Handelman CS, Wang L, BeGole EA, Haas AJ. Nonsurgical rapid maxillary expansion in adults: Report on 47 cases using the Haas expander. *Angle Orthod* 2000; 70(2): 129-44. [PMID: 10833001]
- [36] Garib DG, Henriques JF, Carvalho PE, Gomes SC. Longitudinal effects of rapid maxillary expansion. *Angle Orthod* 2007; 77(3): 442-8. [http://dx.doi.org/10.2319/0003-3219(2007)077[0442:LEORME]2.0.CO;2] [PMID: 17465651]
- [37] Majourau A, Nanda R. Biomechanical basis of vertical dimension control during rapid palatal expansion therapy. *Am J Orthod Dentofacial Orthop* 1994; 106(3): 322-8. [http://dx.doi.org/10.1016/S0889-5406(94)70053-2] [PMID: 8074098]
- [38] Davis WM, Kronman JH. Anatomical changes induced by splitting of the midpalatal suture. *Angle Orthod* 1969; 39(2): 126-32. [PMID: 5252050]
- [39] Pancherz H, Bjerklind K, Hashemi K. Late adult skeletofacial growth after adolescent Herbst therapy: A 32-year longitudinal follow-up study. *Am J Orthod Dentofacial Orthop* 2015; 147(1): 19-28. [http://dx.doi.org/10.1016/j.ajodo.2014.06.011] [PMID: 25533068]

© 2019 Haffaf *et al.*

This is an open access article distributed under the terms of the Creative Commons Attribution 4.0 International Public License (CC-BY 4.0), a copy of which is available at: (<https://creativecommons.org/licenses/by/4.0/legalcode>). This license permits unrestricted use, distribution, and reproduction in any medium, provided the original author and source are credited.