



The Open Dentistry Journal

Content list available at: www.benthamopen.com/TODENTJ/

DOI: 10.2174/1874210601812010995, 2018, 12, 995-1003



RESEARCH ARTICLE

Periosteal Envelope Flap as a Technique for Horizontal Bone Augmentation: A Case Series Study

Sepideh Arab¹, Hamid Reza Arab², Maryam Aghaloo³, Farid Shiezadeh⁴, Shamim Tajik⁴ and Amir Moeintaghavi^{5,*}

¹Private Practice, Mashhad, Iran

²Dental Research Center, Mashhad University of Medical Sciences, Mashhad, Iran

³Dental Research Center, Shahid Beheshti University of Medical Sciences, Tehran, Iran

⁴Department of Periodontics, Mashhad University of Medical Sciences, Mashhad, Iran

⁵Oral & Maxillofacial Diseases Research Center, Mashhad University of Medical Sciences, Mashhad, Iran

Received: April 29, 2018

Revised: October 23, 2018

Accepted: November 18, 2018

Abstract:

Background:

Following tooth extraction, the alveolar bone is typically subject to irrevocable and progressive changes that are collectively referred to as natural bone resorption. This process eventually results in a deficiency of the vertical and horizontal dimensions of the bone. Conventionally, various methods are used to repair alveolar defects resulting from tooth extraction, and to achieve vertical or horizontal bone regeneration. The aim of this study was to evaluate the influence of periosteal pocket flap on the enhancement of horizontal length in alveolar bone regeneration.

Methods:

Twenty-two patients (7 men, 15 women) aged 45–60 years were enrolled in this study. Periosteal envelope flaps and Cerabone were used to increase alveolar bone thickness. Ridge width was measured preoperatively and 4–6 months postoperatively using cone-beam computed tomography. The pre- and postoperative results were compared using the paired t-test.

Results:

An average of 2.53 mm ($P < 0.001$) horizontal enhancement of the alveolar ridge was achieved.

Conclusion:

The results of this study suggest that the use of a periosteal pocket flap with xenograft material is an excellent method which increase more than 2 mm alveolar bone width. As the study sample was small, further clinical investigations with larger samples are recommended.

Keywords: Horizontal augmentation, GBR, Bone graft, Periosteal pocket, Osteogenic cells, Periosteal pocket flap.

1. INTRODUCTION

Implant therapy is known as the best method for the restoration of edentulous sites [1]. Prosthetic implantation requires the presence of sufficient high-quality bone. Resorption of the alveolar process may occur as a consequence of inflammation, trauma, or tooth extraction [2]. Following tooth loss, the adjacent bone resorbs to a greater extent horizontally than vertically in the anterior and posterior regions of the mouth [3, 4]. Some reports describe a 50%

* Address correspondence to this author at the Oral & Maxillofacial Diseases Research Center, Mashhad University of Medical Sciences, Vakilabad Blvd., Mashhad, Iran; Tel: 0098 511 6012189; Fax: 0098 511 8829500; E-mail: Moeintaghavia@mums.ac.ir

decrease in the horizontal dimension of the bone during the 12 months following tooth loss, with two-thirds of this loss occurring within 3 months after extraction [5]. At its onset, bone resorption is observed mainly on the buccal surface; it affects the lingual surface in its advanced stages. Undesirable intermaxillary relationships, periodontal disease, congenital tooth absence, developmental defects, tumors, dehiscence, and fenestration may contribute to bone resorption [6 - 8]. Clearly, sufficient bone volume is a prerequisite for the long-term success of an implant, as it permits correct three-dimensional placement and ensures stability [9]. Therefore, investigations are underway to identify more convenient and effective surgical methods to enhance alveolar bone length.

Steigmann *et al.*, [10], introduced the periosteal pocket flap, which can be used with Bio-Oss® to provide adequate coverage, increasing the alveolar ridge length. The authors reported a nearly three-fold increase in bone length after 6 months of follow-up. Buser and Dula [11] achieved a 98.3% success rate in 61 implantation cases treated previously with autografts and non-absorbable barrier membranes. Fugazzotto [12] used Guided Bone Regeneration (GBR) and reported cumulative success rates of 97.2% in the mandible and 97.4% in the maxilla for 607 implants, the function of which was monitored for up to 133 months. In a systematic review, the survival rate of implants placed in regenerated bone resulting from GBR was similar to that of implants placed in native bone [13]. Another systematic review of the clinical use of grafting materials between 1995 and April 2015, which included 184 papers from the PubMed and Cochrane databases indicated that combined average horizontal and vertical gain of 3.7 mm can be achieved using granular materials [14]. Sanz-Sanchez *et al.*, [15], conducted a systematic review and meta-analysis of 40 clinical studies to assess the efficacy of lateral bone augmentation in relation to alveolar crest dimensions; they found that the use of bone replacement grafts with barrier membranes and the application of autogenous bone blocks both led to high (>95%) success and survival rates.

GBR is a technique used for ridge augmentation. It involves the surgical placement of an absorbable or non-absorbable barrier membrane to stabilize the fibrin clot, maintain a space for osteogenic cells, and exclude cells that impede bone formation (*e.g.*, epithelial cells and fibroblasts) [16 - 18]. One of the most prevalent problems associated with GBR is dehiscence of the soft tissue, which is detrimental to wound healing. To ensure the success of GBR, primary wound closure has been proven to be essential [19 - 22].

Bone autografts continue to be the gold-standard graft materials for bone augmentation due to their remarkable osteogenic properties, which enable harvesting from intraoral sources such as the maxillary tuberosity, chin, and mandibular ramus, as well as from extraoral sources such as the hip [23 - 26]. The most important risk to consider when using autografts is donor-site morbidity [27, 28].

When using GBR to achieve horizontal or vertical regeneration, the soft tissue should be mobile to attain effective closure. Soft-tissue dehiscence often necessitates premature removal of a non-absorbable barrier membrane, which is not true of a collagen membrane [29, 30]. Materials exposed to the intraoral environment degenerate more rapidly, jeopardizing the final outcome [22]. To avert exposure of the wound, the flap is usually applied and stretched to a great extent. The periosteum is then removed from its base. Making such an incision in dental periosteum is bound to damage the periosteal vessels and the upper vascular network, to the detriment of the local blood supply. The periosteal pocket flap was designed to address this issue. The periosteum is carefully removed from the mucosal coverage at the mucogingival junction with a blunt instrument, which is expected to maintain the integrity of the vessels in the periosteum-free mucosal flap and those within the periosteum, facilitating local blood supply. The mucosa is free and can passively and effectively cover the area; the membrane is placed under the periosteum and the periosteum is sutured to the lingual flap, which fixes the membrane completely, making the application of a fixture device unnecessary [10].

The aim of this study was to evaluate the effect of periosteal pocket flap use on the enhancement of horizontal length in alveolar bone regeneration.

2. MATERIALS AND METHODS

2.1. Subjects and Sample Collection

In this case-series study, samples were collected in a randomized and task-oriented order. Patients who were referred to professional periodontology clinics in the city of Tehran were enrolled.

The Board of Research and Ethics Committee of Shahid Beheshti University of Medical Sciences, Tehran, Iran, approved this study and written informed consent was obtained from all participants. Patients admitted to a private clinic for implant-based therapy who had narrow ridges that did not permit conventional implant placement (*e.g.*,

synchronous implantation and augmentation) were eligible for this study. The treatment plan, including possible side effects and benefits of the procedure, was explained to the subjects. Patients were assured for the anonymity of their data. Comprehensive periodontal examination of the remaining teeth, including the assessment of pocket depth, bleeding on probing, and tooth mobility, was performed. Patients who smoked and those with systemic diseases (*e.g.*, diabetes, osteoporosis), parafunctional habits, histories of immunosuppressive drug or bisphosphonate use, and/or edentulous areas encompassing more than four tooth sites were excluded.

Prior to the procedure, patients were evaluated using Cone-Beam Computed Tomography (CBCT; ProMax 3D Mid; Planmeca Oy, Finland, Helsinki). On the images, ridge thickness was summed in 2-mm increments; the total was then divided by the number of sections to obtain an average ridge thickness for each patient. Patients with ridge widths < 4 mm were included in the study (Fig. 1). First, the patients were draped and prepared, including the perioral application of povidone iodine. Then, local anesthesia was achieved by administering one or two cartridges of 2% lidocaine with 1:80,000 epinephrine (Persocaine E; Darupakhsh, Tehran, Iran) at the injection site (Fig. 2A). Surgery was initiated 10 min later. Initially, a crestal incision was made to the desired length with a #15 scalpel. Then, a transverse line was delicately incised on the periosteum using a scalpel to create a shallow gap. The gap was then deepened with a periosteal elevator, completely detaching the mucosa from the periosteum (Fig. 2B). When necessary, a vertical releasing incision was made in the mesial area of the attached gingiva, proximal to the crestal incision and extending to the mucogingival junction. A similar incision was made in the distal area. At this stage, the mucosal flaps were lifted to the mucogingival junction using an elevator. Next, the periosteum was removed from the bone with a periosteal elevator to create a pocket equal in size to the intended augmentation (Fig. 2C). As no releasing incision had been made on the periosteum, this pocket was formed to accommodate the graft material and membrane. An absorbable collagen membrane (Jason) (Botiss Dental, Berlin, Germany) and a sufficient quantity of Cerabone powder (Botiss Dental, Berlin, Germany) were placed inside the pocket (Fig. 2D).

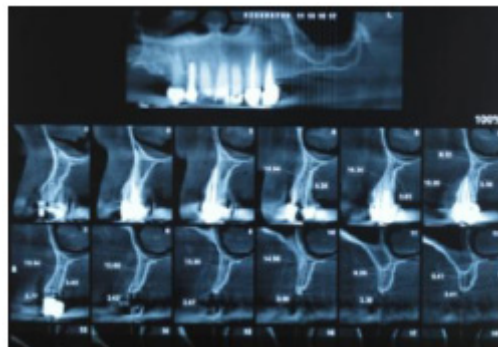


Fig. (1). Preoperative CBCT.

The membrane was positioned on the graft material so that its edge rested under the lingual flap. Then, the periosteum was sutured to the membrane, extending to the lingual flap, with a range of sutures (vicryl 0-3; SUPA Medical Devices, Tehran, Iran) (Fig. 2E). The buccal flap, which contained the alveolar mucosa and attached gingiva, was sutured to the lingual side (Fig. 2F).

2.2. Postoperative Instructions

After surgery, patients were prescribed amoxicillin (500 mg every 8 h; Kosar, Tehran, Iran) and analgesics (*e.g.*, acetaminophen, codeine). Patients were advised to refrain from having any prosthesis placed in the area of the graft until 4 months postoperatively, and to consume a soft diet for 24 h following the operation up to 10 days. And then sutures were removed 2 weeks after surgery.

At 4 - 6 months postoperatively (Fig. 2G), follow-up CBCT images were obtained to determine the dimensional changes that had occurred and the appropriate implant size (Fig. 3). Preoperative and postoperative images were used to quantify the longitudinal enhancement of the ridge for each individual. Suitable implants were inserted subsequently (Fig. 4).

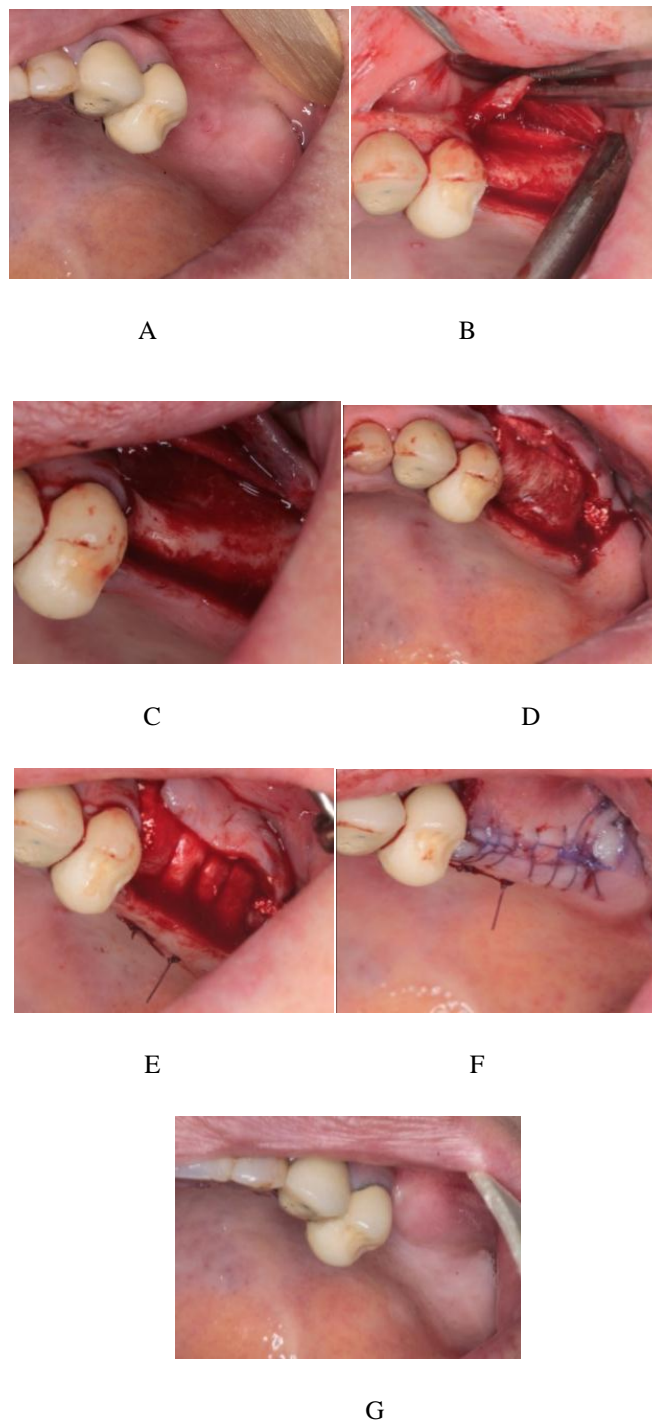


Fig. (2). A: Patient mucosa before incision B: periosteal incision and detaching the mucosa C: creating periosteal pocket for bone graft D: membrane placement under the pocket and lingual flap E: periosteal suturing over the membrane with vicryl thread F: suturing mucosa on the graft without tension G: follow up after 6 months.

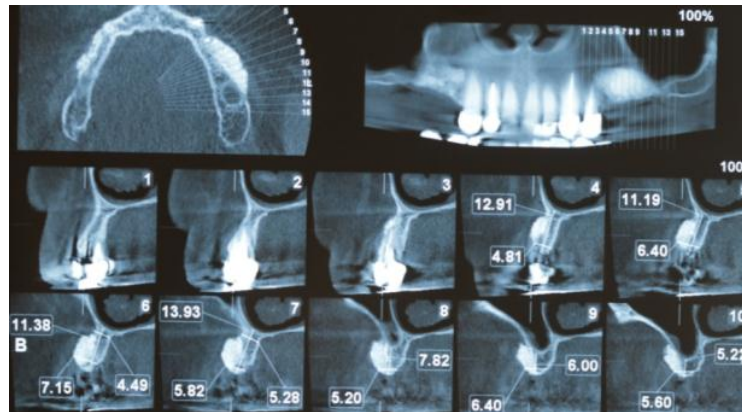


Fig. (3). Postoperative CBCT in 6 months follow up.

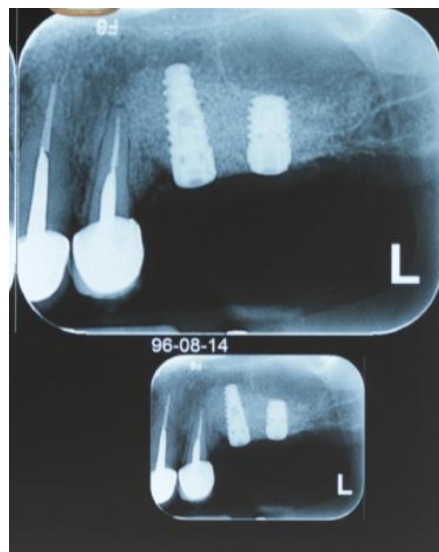

Fig. (4). Implant placement after successful augmentation and 6 months follow up.

2.3. Statistical Analysis

The Shapiro-Wilk test was used to evaluate the normality of the data. As the data distribution was normal, the paired *t*-test was used to assess the mean change in bone width.

3. RESULTS

In total, 22 patients (7 (32%) men, 15 (68%) women) were enrolled in this study. The average age was 48.74 ± 8.79 (range, 40 - 65) years. The mean preoperative and postoperative ridge widths were 2.94 and 5.47 mm, respectively. The mean increase in ridge width (2.53 mm) was significant ($P < 0.001$, $t = 13.21$) (Table 1) no wound dehiscence or infection was recorded 4 - 6 months postoperatively.

Table 1. The Mean and Standard Deviation of the ridge width before and after augmentation surgery.

-	Mean	Min	Max	SD*	T-test Result
Pre op width	2.94 mm	1.98 mm	4.3 mm	0.57	T=13.21 P< 0.001
Post op width	5.47 mm	4.21 mm	6.86 mm	0.71	
Differentiation	2.53	2.23	2.56	-	

*Standard Deviation

The 22 patients had in total 24 implants installed and all of the implants were Biohorizons (Birmingham, USA) with standard diameter.

4. DISCUSSION

Endosseous implants have recently become a reliable treatment option for partially or completely edentulous patients. However, implant therapy requires a sufficient volume of high-quality bone to ensure the attainment of favorable aesthetic and functional outcomes. In some cases, implant placement is difficult or impossible due to bone resorption. Bone transplantation can be performed with various kinds of graft; the use of autogenous grafts for this purpose is currently considered to be the gold standard.

Autografts are osteogenic, osteoconductive, and osteoinductive [31]. They can be harvested from intraoral and extra oral sources. Although their use is highly advantageous, they pose minimal risks of infection and immunological reactions after grafting. Arab *et al.*, [32] applied bone autografts harvested noninvasively with a trephine drill and achieved an acceptable increase in ridge width. However, the most important drawback of this type of graft is that it entails two simultaneous surgeries.

In this study, a xenograft material obtained from the mineral phase of bovine bone (Cerabone; Botiss Dental) was used. Cerabone® has a strong resemblance to human bone in terms of surface porosity and chemical composition. Xenografts are osteoconductive and osteoinductive [29, 33, 34].

The significant increase in mean bone width observed in this study was comparable to the results of studies which have been performed with more difficult techniques.

Buser and colleagues evaluated augmented ridge with autogenous bone. the mean ridge width increased from 3.7 mm to 7.1 mm and reported high survival rate for implant inserted in augmented bone. their result is more than of our paper that showed the autogenous bone is the gold standard for ridge augmentation yet. autogenous block graft and longer follow up period are the reasons for this impressive bone gain [20].

Funaki *et al.*, used distraction osteogenesis techniques to increase ridge width by 2.7 that somewhat resembles to our study [35].

in the study by Kelly the tunnel technique with xenograft particle used for ridge augmentation, and up to 6 mm increasing in ridge width achieved. Their results were along with our study and showed that these techniques are predictable [36].

Moeintaghavi *et al.*, in a study investigated demineralized cancellous bone block graft for horizontal ridge augmentation and showed $52/1 \pm 28/1$ mm enhancing in ridge width that is lower than that of our result. the limited number of patients and using cancellous block graft are the main causative factors of such weak bone gain [37].

Steigmann *et al.*, used the periosteal pocket flap technique in atrophic ridge of 5 patients with xenograft and after 6 months cone beam computed tomography showed 389% increase in ridge width that is in line of our study but with significant more bone gain. The limited number of cases and limited area of edentulous ridge may be the reason of greater result of Steigmann study [10].

Periosteal pocket flap in this study provides predictable GBR outcome based on primary wound closure, wound stability along with angiogenesis. Primary closure provide the best environment for healing period without bacterial and mechanical disturbance that enhances surgical outcomes.

Angiogenesis, in this technique enhances the cortical perforation and wound stability. Decortication results in traveling pluripotent cell to migrate from bone marrow to the bone graft and to maximize mechanical interlocking between the graft and the host tissue.

This technique increases the stability of membrane and graft material with periost and periosteal suturing, even in cases of severe bone deficiencies.

Clot stabilization is the key factor for optimal healing outcome with recruiting cell and growth factors in the wound site and this results in predictable regeneration [19, 20, 22, 29, 32].

In this article, a 35% soft tissue dehiscence has been shown after GBR procedure. Without primary wound closure, significant reduction in bone regeneration has been observed and bacterial colonization in healing period has been the reason for this phenomenon which jeopardized the GBR results [22].

Friedman *et al.*, [21], used cross-linked collagen membranes to achieve alveolar crest augmentation in 16 patients, and observed wound disruption and exposure in 62.5% (10/16) of cases. Norton *et al.*, [38] used bovine and collagen membranes for sinus augmentation and employed GBR to increase horizontal thickness. The exposed membranes were

observed in 26% of cases, two of which showed little or no new bone formation on histological examination. Hiatt and Schallhorn [39] showed that proper soft-tissue coverage increased the likelihood of bone regeneration. Three types of complication were observed in a study involving vertical augmentation with demineralized bovine bone and implant placement; one of these was the complete loss of augmentation after soft-tissue defects in 3 - 8 weeks earlier [40]. Thus, membrane exposure is a common and disruptive complication of GBR. Because the periosteal pocket technique permits tension free closure and hypermobility of the mucosa flap the number of soft tissue dehiscences decreased.

The strengths of this study include our demonstration that the periosteal pocket flap enables prevention of postoperative wound dehiscence and the achievement of full membrane coverage with soft tissue without flap stretching. Nonetheless, the study has several limitations, including the small sample. In addition, no histological examination or long-term follow-up was performed after the implantation procedure.

CONCLUSION

This study demonstrated that the use of a periosteal pocket flap with GBR provided an acceptable increase in ridge width. The authors recommend further clinical studies with larger samples, postoperative histological examination, and long-term follow-up.

ETHICS APPROVAL AND CONSENT TO PARTICIPATE

The Board of Research and Ethics Committee of Shahid Beheshti University of Medical Sciences, Tehran, Iran, approved this study.

HUMAN AND ANIMAL RIGHTS

No animals were used in this research. All human research procedures followed were in accordance with the ethical standards of the committee responsible for human experimentation (institutional and national), and with the Helsinki Declaration of 1975, as revised in 2013.

CONSENT FOR PUBLICATION

Written informed consent was obtained from all participants before their participation.

CONFLICT OF INTEREST

The authors declare no conflict of interest, financial or otherwise.

ACKNOWLEDGEMENTS

Declared none.

REFERENCES

- [1] Shimono K, Oshima M, Arakawa H, Kimura A, Nawachi K, Kuboki T. The effect of growth factors for bone augmentation to enable dental implant placement: A systematic review. *Jpn Dent Sci Rev* 2010; 46(1): 43-53. [<http://dx.doi.org/10.1016/j.jdsr.2009.10.004>]
- [2] von Arx T, Buser D. Horizontal ridge augmentation using autogenous block grafts and the guided bone regeneration technique with collagen membranes: A clinical study with 42 patients. *Clin Oral Implants Res* 2006; 17(4): 359-66. [eng.]. [<http://dx.doi.org/10.1111/j.1600-0501.2005.01234.x>] [PMID: 16907765]
- [3] Johnson K. A study of the dimensional changes occurring in the maxilla following tooth extraction. *Aust Dent J* 1969; 14(4): 241-4. [eng.]. [<http://dx.doi.org/10.1111/j.1834-7819.1969.tb06001.x>] [PMID: 5259350]
- [4] Lekovic V, Camargo PM, Klokkevold PR, *et al.* Preservation of alveolar bone in extraction sockets using bioabsorbable membranes. *J Periodontol* 1998; 69(9): 1044-9. [eng.]. [<http://dx.doi.org/10.1902/jop.1998.69.9.1044>] [PMID: 9776033]
- [5] Schropp L, Wenzel A, Kostopoulos L, Karring T. Bone healing and soft tissue contour changes following single-tooth extraction: A clinical and radiographic 12-month prospective study. *Int J Periodontics Restorative Dent* 2003; 23(4): 313-23. [eng.]. [PMID: 12956475]
- [6] Chiapasco M, Zaniboni M, Boisco M. Augmentation procedures for the rehabilitation of deficient edentulous ridges with oral implants. *Clin Oral Implants Res* 2006; 17(Suppl. 2): 136-59. [eng.]. [<http://dx.doi.org/10.1111/j.1600-0501.2006.01357.x>] [PMID: 16968389]
- [7] De Angelis N, Scivetti M. Lateral ridge augmentation using an equine flex bone block infused with recombinant human platelet-derived

- growth factor BB: A clinical and histologic study. *Int J Periodontics Restorative Dent* 2011; 31(4): 383-8. [eng.].
[PMID: 21837304]
- [8] Seibert JS. Reconstruction of deformed, partially edentulous ridges, using full thickness onlay grafts. Part II. Prosthetic/periodontal interrelationships. *Compend Contin Educ Dent* 1983; 4(6): 549-62. [eng.].
[PMID: 6321099]
- [9] Buser D, Martin W, Belser UC. Optimizing esthetics for implant restorations in the anterior maxilla: Anatomic and surgical considerations. *Int J Oral Maxillofac Implants* 2004; 19(Suppl.): 43-61. [eng.].
[PMID: 15635945]
- [10] Steigmann M, Salama M, Wang HL. Periosteal pocket flap for horizontal bone regeneration: A case series. *Int J Periodontics Restorative Dent* 2012; 32(3): 311-20. [eng.].
[PMID: 22408776]
- [11] Buser D, Ingimarsson S, Dula K, Lussi A, Hirt HP, Belser UC. Long-term stability of osseointegrated implants in augmented bone: A 5-year prospective study in partially edentulous patients. *Int J Periodontics Restorative Dent* 2002; 22(2): 109-17. [eng.].
[PMID: 12019706]
- [12] Fugazzotto PA. Success and failure rates of osseointegrated implants in function in regenerated bone for 72 to 133 months. *Int J Oral Maxillofac Implants* 2005; 20(1): 77-83. [eng.].
[PMID: 15747677]
- [13] Hämmerle CH, Jung RE, Feloutzis A. A systematic review of the survival of implants in bone sites augmented with barrier membranes (guided bone regeneration) in partially edentulous patients. *J Clin Periodontol* 2002; 29(Suppl. 3): 226-31. [eng.].
[http://dx.doi.org/10.1034/j.1600-051X.29.s3.14.x] [PMID: 12787222]
- [14] Troeltzsch M, Troeltzsch M, Kauffmann P, et al. Clinical efficacy of grafting materials in alveolar ridge augmentation: A systematic review. *J Craniomaxillofac Surg* 2016; 44(10): 1618-29. [eng.].
[http://dx.doi.org/10.1016/j.jcms.2016.07.028] [PMID: 27622971]
- [15] Sanz-Sánchez I, Ortiz-Vigón A, Sanz-Martín I, Figuero E, Sanz M. Effectiveness of lateral bone augmentation on the alveolar crest dimension: A systematic review and meta-analysis. *J Dent Res* 2015; 94(9)(Suppl.): 128S-42S. [eng.].
[http://dx.doi.org/10.1177/0022034515594780] [PMID: 26215467]
- [16] Buser D, Brägger U, Lang NP, Nyman S. Regeneration and enlargement of jaw bone using guided tissue regeneration. *Clin Oral Implants Res* 1990; 1(1): 22-32. [eng.].
[http://dx.doi.org/10.1034/j.1600-0501.1990.010104.x] [PMID: 2099209]
- [17] Lang NP, Hämmerle CH, Brägger U, Lehmann B, Nyman SR. Guided tissue regeneration in jawbone defects prior to implant placement. *Clin Oral Implants Res* 1994; 5(2): 92-7. [eng.].
[http://dx.doi.org/10.1034/j.1600-0501.1994.050205.x] [PMID: 7918914]
- [18] Nyman S, Lang NP, Buser D, Brägger U. Bone regeneration adjacent to titanium dental implants using guided tissue regeneration: A report of two cases. *Int J Oral Maxillofac Implants* 1990; 5(1): 9-14. [eng.].
[PMID: 2391139]
- [19] Buser D, Dula K, Belser UC, Hirt HP, Berthold H. Localized ridge augmentation using guided bone regeneration. II. Surgical procedure in the mandible. *Int J Periodontics Restorative Dent* 1995; 15(1): 10-29. [eng.].
[PMID: 7591520]
- [20] Buser D, Dula K, Hirt HP, Schenk RK. Lateral ridge augmentation using autografts and barrier membranes: A clinical study with 40 partially edentulous patients. *J Oral Maxillofac Surg* 1996; 54(4): 420-32. [eng.].
[http://dx.doi.org/10.1016/S0278-2391(96)90113-5] [PMID: 8600258]
- [21] Friedmann A, Strietzel FP, Marezki B, Pitaru S, Bernimoulin JP. Observations on a new collagen barrier membrane in 16 consecutively treated patients. Clinical and histological findings. *J Periodontol* 2001; 72(11): 1616-23. [eng.].
[http://dx.doi.org/10.1902/jop.2001.72.11.1616] [PMID: 11759875]
- [22] Moses O, Pitaru S, Artzi Z, Nemcovsky CE. Healing of dehiscence-type defects in implants placed together with different barrier membranes: A comparative clinical study. *Clin Oral Implants Res* 2005; 16(2): 210-9. [eng.].
[http://dx.doi.org/10.1111/j.1600-0501.2004.01100.x] [PMID: 15777331]
- [23] Cordaro L, Amadé DS, Cordaro M. Clinical results of alveolar ridge augmentation with mandibular block bone grafts in partially edentulous patients prior to implant placement. *Clin Oral Implants Res* 2002; 13(1): 103-11. [eng.].
[http://dx.doi.org/10.1034/j.1600-0501.2002.130113.x] [PMID: 12005140]
- [24] McCarthy C, Patel RR, Wragg PF, Brook IM. Dental implants and onlay bone grafts in the anterior maxilla: analysis of clinical outcome. *Int J Oral Maxillofac Implants* 2003; 18(2): 238-41. [eng.].
[PMID: 12705302]
- [25] Raghoobar GM, Schoen P, Meijer HJ, Stellingsma K, Vissink A. Early loading of endosseous implants in the augmented maxilla: A 1-year prospective study. *Clin Oral Implants Res* 2003; 14(6): 697-702. [eng.].
[http://dx.doi.org/10.1046/j.0905-7161.2003.00953.x] [PMID: 15015944]
- [26] Rocuzzo M, Ramieri G, Spada MC, Bianchi SD, Berrone S. Vertical alveolar ridge augmentation by means of a titanium mesh and autogenous bone grafts. *Clin Oral Implants Res* 2004; 15(1): 73-81. [eng.].

- [http://dx.doi.org/10.1111/j.1600-0501.2004.00998.x] [PMID: 14731180]
- [27] Nkenke E, Radespiel-Tröger M, Wiltfang J, Schultze-Mosgau S, Winkler G, Neukam FW. Morbidity of harvesting of retromolar bone grafts: A prospective study. *Clin Oral Implants Res* 2002; 13(5): 514-21. [eng.].
[http://dx.doi.org/10.1034/j.1600-0501.2002.130511.x] [PMID: 12453129]
- [28] Pommer B, Tepper G, Gahleitner A, Zechner W, Watzek G. New safety margins for chin bone harvesting based on the course of the mandibular incisive canal in CT. *Clin Oral Implants Res* 2008; 19(12): 1312-6. [eng.].
[http://dx.doi.org/10.1111/j.1600-0501.2008.01590.x] [PMID: 19040448]
- [29] Simion M, Baldoni M, Rossi P, Zaffe D. A comparative study of the effectiveness of e-PTFE membranes with and without early exposure during the healing period. *Int J Periodontics Restorative Dent* 1994; 14(2): 166-80. [eng.].
[PMID: 7928132]
- [30] Zitzmann NU, Naef R, Schärer P. Resorbable versus nonresorbable membranes in combination with Bio-Oss for guided bone regeneration. *Int J Oral Maxillofac Implants* 1997; 12(6): 844-52. [eng.].
[PMID: 9425767]
- [31] Rosenberg E, Rose LF. Biologic and clinical considerations for autografts and allografts in periodontal regeneration therapy. *Dent Clin North Am* 1998; 42(3): 467-90. [eng.].
[PMID: 9700450]
- [32] Arab HR, Moeintaghavi A, Taheri M, Sargolzaie N, Aghasizadeh D, Shiezadeh F. Lateral Ridge Augmentation with Autogenous Bone Harvested Using Trephine Drills: A Noninvasive Technique. *Open Dent J* 2016; 10: 1-11. [eng.].
[http://dx.doi.org/10.2174/1874210601610010001] [PMID: 27006718]
- [33] Oh TJ, Meraw SJ, Lee EJ, Giannobile WV, Wang HL. Comparative analysis of collagen membranes for the treatment of implant dehiscence defects. *Clin Oral Implants Res* 2003; 14(1): 80-90. [eng.].
[http://dx.doi.org/10.1034/j.1600-0501.2003.140111.x] [PMID: 12562369]
- [34] Park SH, Lee KW, Oh TJ, Misch CE, Shotwell J, Wang HL. Effect of absorbable membranes on sandwich bone augmentation. *Clin Oral Implants Res* 2008; 19(1): 32-41. [eng.].
[PMID: 17956570]
- [35] Funaki K, Takahashi T, Yamuchi K. Horizontal alveolar ridge augmentation using distraction osteogenesis: comparison with a bone-splitting method in a dog model. *Oral Surg Oral Med Oral Pathol Oral Radiol Endod* 2009; 107(3): 350-8. [eng.].
[http://dx.doi.org/10.1016/j.tripleo.2008.10.005] [PMID: 19121955]
- [36] Block MS, Kelley B. Horizontal posterior ridge augmentation: the use of a collagen membrane over a bovine particulate graft: technique note. *J Oral Maxillofac Surg* 2013; 71(9): 1513-9. [eng.].
[http://dx.doi.org/10.1016/j.joms.2013.05.015] [PMID: 23948364]
- [37] Moeintaghavi A, Arab HR, Jabbareh L, Shiezadeh F, Taheri M, Shahmohammadi R. Clinical and radiographic evaluation of demineralized freeze-dried cancellous block allograft for ridge augmentation: A pilot study. *J Long Term Eff Med Implants* 2016; 26(4): 329-36. [eng.].
[http://dx.doi.org/10.1615/JLongTermEffMedImplants.2017017812] [PMID: 29199618]
- [38] Norton MR, Odell EW, Thompson ID, Cook RJ. Efficacy of bovine bone mineral for alveolar augmentation: A human histologic study. *Clin Oral Implants Res* 2003; 14(6): 775-83. [eng.].
[http://dx.doi.org/10.1046/j.0905-7161.2003.00952.x] [PMID: 15015955]
- [39] Hiatt WH, Schallhorn RG. Intraoral transplants of cancellous bone and marrow in periodontal lesions. *J Periodontol* 1973; 44(4): 194-208. [eng.].
[http://dx.doi.org/10.1902/jop.1973.44.4.194] [PMID: 4570483]
- [40] Draenerer FG, Kämmerer PW, Berthold M, Neff A. Complications with allogeneic, cancellous bone blocks in vertical alveolar ridge augmentation: Prospective clinical case study and review of the literature. *Oral Surg Oral Med Oral Pathol Oral Radiol* 2016; 122(2): e31-43. [eng.].
[http://dx.doi.org/10.1016/j.oooo.2016.02.018] [PMID: 27236830]