

Iatrogenic Damage to the Periodontium Caused by Orthodontic Treatment Procedures: An Overview

Syed Rafiuddin^{1,*}, Pradeep Kumar YG², Shriparna Biswas³, Sandeep S. Prabhu³, Chandrashekar BM³ and Rakesh MP³

¹Department of Orthodontics, Sri Hasanamba Dental College & Hospital, Hassan, Karnataka, India; ²Department of Oral Medicine & Radiology, Government Dental College & Hospital & Research Institute, Bellary, Karnataka, India; ³Department of Periodontology, Rajarajeswari Dental College & Hospital, Bangalore-560074, Karnataka, India

Abstract: In orthodontic treatment, teeth are moved in to new positions and relationships and the soft tissue and underlying bone are altered to accommodate changes in esthetics and function. Function is more important than esthetics. The speciality of orthodontics has in addition to its benefits, complications as well as risks associated with its procedures. However the benefits outweigh the risks & complications in most of the treatment cases. Few of the unwanted side effects associated with treatment are tooth discolorations, enamel decalcification, periodontal complications like open gingival embrasures, root resorption, allergic reactions to nickel & chromium as well as treatment failure in the form of relapse.

Keywords: Iatrogenic, orthodontics, periodontium, tooth movement.

INTRODUCTION

Increased life expectancy, improved socio-economic conditions along with a desire for improved self esteem has resulted in an increase of adult population seeking orthodontic treatment. Furthermore, the changing concepts of esthetics with the advent of esthetic brackets & arch wires have combined functional benefits with esthetics. In orthodontic treatment, teeth are moved into new positions and relationships and the soft tissue and underlying bone are altered to accommodate changes in esthetics and function. Function is more important than esthetics. The speciality of orthodontics has in addition to its benefits, complications as well as risks associated with its procedures. However the benefits outweigh the risks & complications in most of the treatment cases. Few of the unwanted side effects associated with treatment are tooth discolorations, enamel decalcification, periodontal complications like open gingival embrasures, root resorption, allergic reactions to nickel & chromium as well as treatment failure in the form of relapse.

Few of the malocclusions which affect the periodontium such as anterior deep bite can cause stripping of the labial gingiva of lower anteriors and lingual gingiva of upper anteriors. Anterior cross bite can cause localized gingival recession & mobility of the affected tooth. Correcting these malocclusions with orthodontic treatment will help to improve the periodontal status and overall health of an individual.

Dental plaque has been established as a potential risk factor for the development of periodontal diseases and the progression of these diseases depends on the balance between microbial biofilms and immune and inflammatory host

responses [1]. The undesirable side effects of orthodontic treatment are tissue damage, treatment failure & increased predisposition to dental disorders.

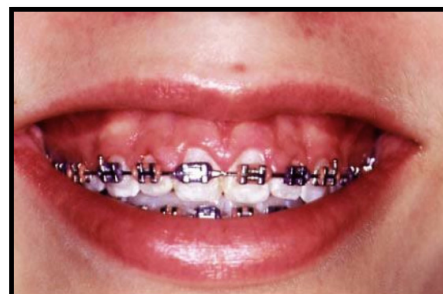

Fig. (1). Gingival inflammation caused by orthodontic brackets.

Studies have shown that the presence of orthodontic appliances in the oral cavity increases the amount of plaque, resulting in the formation of gingival hyperplasia & pseudo-pockets [2] (Fig. 1). This changes the subgingival ecosystem thereby causing an increase in periodontal pathogen levels which stimulate the host cells to release various types of inflammatory cytokines such as interleukin 1 β (IL-1 β), interleukin 6 (IL-6), interleukin 8, (IL-8) and growth factors such as tumor growth factor (TGF) [3]. Orthodontic tooth movement causes reorientation & remodeling of supporting periodontal tissues. When optimum orthodontic forces are applied it causes expected reactions in the supporting periodontal tissues.

POTENTIAL ADVERSE EFFECTS TO THE PERIODONTAL TISSUES

Plaque is considered as the major etiological factor in the development of gingivitis [4].

*Address correspondence to this author at the Department of Orthodontics, Hasanamba Dental College and Hospital, Hassan, Karnataka, India; Tel: 08050966179; E-mail: drsyedrafi786@gmail.com

Experimental animal studies have shown that orthodontic forces & tooth movements do not induce gingivitis in the absence of plaque [5]. However similar forces can induce angular bone defects in the presence of plaque. Orthodontic tooth movements like tipping & intrusion can cause attachment loss in the presence of plaque [6]. Healthy, reduced periodontal tissue support regions do not cause gingival inflammation when orthodontic forces are kept within the optimum limits [7]. Plaque is considered as the most important factor in the initiation, progression and recurrence of periodontal diseases in reduced periodontium [8].

In most patients a transient gingival inflammation occurs after placement of fixed appliances which usually does not lead to attachment loss [9, 10] Gingival hyperplasia can develop around orthodontic bands leading to pseudo pocket formation. However this condition resolves after few days of debanding.

The importance of plaque control and good oral hygiene must be stressed to the patient before starting the fixed appliance treatment and adequate patient compliance must be ensured throughout treatment to prevent gingival inflammation.

ATTACHMENT LOSS

In many orthodontic patients, mechanical irritation caused by the bands or cement is the principal reason for the associated gingival and periodontal inflammation along with plaque [11]. Attachment loss can be a major risk in the presence of iatrogenic irritants [12]. Histological study conducted on human periodontal tissues confirmed that orthodontic banding have to be performed with great care along with excellent oral hygiene in order to avoid permanent periodontal destruction [13].

A review of the evidence-based literature [14] conducted in the field of periodontics & orthodontics showed that with optimum forces, good oral hygiene and the absence of pre existing periodontal disorders no periodontal risk occurs to the patients [15]. However poor oral hygiene & preexisting untreated periodontal disorders can lead to significant & permanent periodontal damage with fixed appliances & various tooth movements [16].

Adult patients with some pre-existing periodontal disease are at a higher risk of developing periodontal problems [17]. Orthodontic treatment is not contraindicated in this group of patients if they are motivated to maintain good oral hygiene & the disease is kept under control throughout the duration of treatment [18]. Assessment of periodontal status prior to fixed appliance treatment is of utmost importance and any pre-existing problems must be treated before initiating the treatment. Regular periodontal checkups & routine oral prophylaxis are advisable to keep the periodontal disease under control [19].

Patients with pre-existing periodontal problems and bone loss must be referred to and treated by the periodontist before initiating the orthodontic treatment [20]. Moreover, in such patients, there is a slight modification in the biomechanics with the application of minimal and optimum orthodontic forces, keeping in mind the shortened root support [21].

BLACK TRIANGLES

Gingival Embrasures are Defined as the Embrasure Existing Cervical to the Interproximal Contact [22]

Open gingival embrasures occur when the embrasure space is not completely covered by gingival tissue leading to retention of food debris & adversely affecting the periodontium. This condition is more common in adult patients with bone loss [23].

Black triangle Fig. (2) or open gingival embrasure can occur as a complication in about 1/3 of all adult patients & it should be discussed with patients before initiating orthodontic treatment [24].

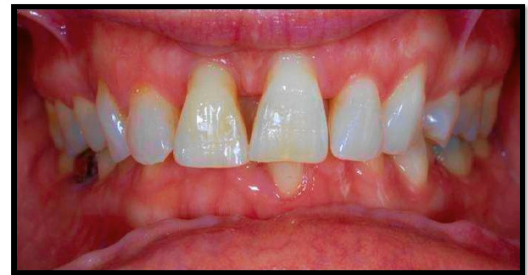

Fig. (2). Black triangle.

Preserving the interdental papilla & avoiding formation of black triangles in the esthetic zone forms a key consideration in orthodontic & restorative treatment.

In a survey conducted orthodontists perceived a 2 mm open gingival embrasure as noticeably less attractive when compared with a patient with normal gingival embrasures [25]. Open gingival embrasures greater than 3 mm were perceived as less attractive by both general dentists & general population.

Few of the aspects which should be taken into consideration when treating a patient with reduced bone support are the risk of further bone loss which might lead to the loss of teeth, & a change in appliance as well as treatment mechanics [26]. Orthodontic forces may lead to the destruction of periodontal bone support through the induction of pro-inflammatory cytokines & also by decreasing the expression of matrix proteins and osteogenic protein [27]. Irritation factors, such as ill-fitting band margins, variable form and dimension of the interdental embrasure during movement and tooth movement itself exerts a toll on the periodontium.

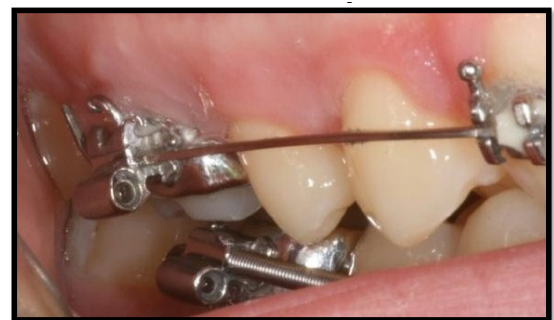

Fig. (3). Mucosal trauma caused by a fixed appliance component.

There are 4 significant factors regarding occlusal traumatism that should be re-emphasized.

1. Occlusal traumatism by itself does not cause pocket formation or gingivitis.
2. Occlusal trauma by itself can cause tooth mobility, bone resorption and widening of the PDL space.
3. Local irritants, microbial plaque and environmental conditions that harbor plaque can cause pocket formation, apical migration of the junctional epithelium, attachment and bone loss.
4. A combination of local irritants and occlusal traumatism causes more rapid destruction than do local factors themselves.

Gingival and Periodontal changes related to orthodontic treatment are, in general transient with no permanent damage. Loss of attachment and alveolar bone loss are known to occur during orthodontic treatment, but are reported to be temporary [28]. But if long term orthodontic treatment continues in the absence of oral hygiene, then gingival and periodontal damage takes place. Deleterious effects includes gingivitis, mucosal trauma (Fig. 3), gingival hyperplasia, marginal periodontitis, gingival recession mostly at extraction areas, loss of attachment, inter dental clefts, mostly at the vestibular aspects of extracted mandibular first premolar site, reduced width of keratinized gingiva and marginal bone and apical root resorption. Some of these undermine the stability of the orthodontic result, particularly where there is a reduction in the bone support or presence of gingival clefts or recession.

Periodontitis Caused by Orthodontic Treatment

Exaggerated plaque accumulation during orthodontic treatment may facilitate the formation of localized, deep anaerobic pockets in which periodontal pathogens may flourish and the situation may deteriorate in to a more serious condition. Gingiva initially becomes inflamed, owing to plaque accumulation and later patient complains of pain and bleeding. Clinical examination will then reveal a hemorrhagic gingiva and pocket that extends to the furcation Figs. (4, 5).

GINGIVAL RECESSION AND CLEFTS

Gingival recession (receding gums) (Figs. 6, 7), is the exposure in the roots of the teeth caused by a loss of gum tissue and/or retraction of the gingival margin from the crown of the teeth.

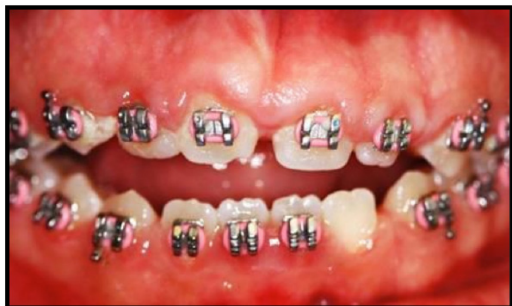

Fig. (4). Inflammatory gingival enlargement of labial anterior gingiva during orthodontic treatment.

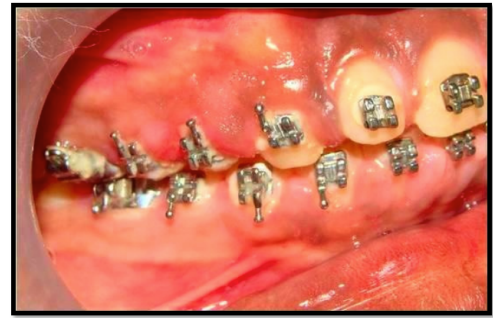

Fig. (5). Right lateral view showing inflammatory enlargement.

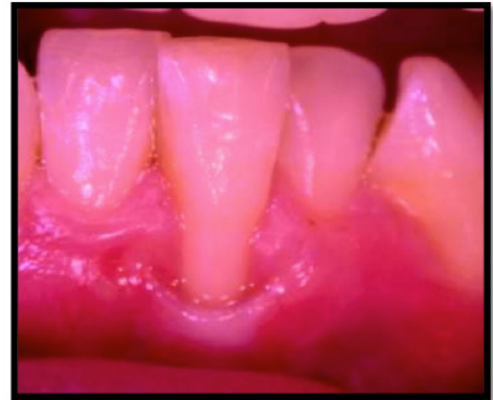

Fig. (6). Gingival recession.

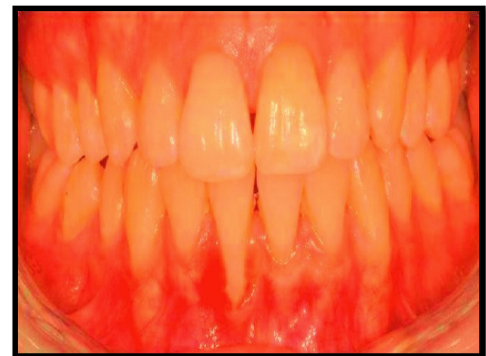

Fig. (7). Gingival recession.

Several classification systems are in use to help diagnose gingival recession:

- Sullivan & Atkins 1968
- Mlinek *et al.* 1973
- Miller 1985 Smith 1997
- Mahajan 2010

The most commonly used is the Miller's classification which:

- Divides gingival recession defects into 4 categories.
- Evaluates both soft and hard tissue loss.
- Determines the level of root coverage achievable with a free gingival graft.
- It is therefore diagnostic and prognostic.

Miller's Classification**Class I**

- Marginal tissue recession which does not extend to the mucogingival junction (MGJ).
- There is no alveolar bone loss or soft tissue loss in the inter-dental area.
- Complete root coverage obtainable.

Class II

- Marginal tissue recession which extends to or beyond the MGJ.
- There is no alveolar bone loss or soft tissue loss in the interdental area.
- Complete root coverage obtainable.

Class III

- Marginal tissue recession which extends to or beyond the MGJ.
- Bone or soft tissue loss in the inter dental area is present.
- Partial root coverage related to level of papilla height.

Class IV

- Marginal tissue recession which extends to or beyond the MGJ.
- The bone or soft tissue loss in the inter dental area is present with gross flattening.
- No root coverage.

One of the most common esthetic concerns associated with the periodontal tissues is gingival recession. Gingival recession is the exposure of root surfaces due to apical migration of the gingival tissue margins. Gingival margin migrates apical to the cemento-enamel junction. Although it rarely results in tooth loss, marginal tissue recession is associated with thermal and tactile sensitivity, esthetic complaints, and a tendency toward root caries.

An adequate width of attached gingiva is necessary for healthy periodontal tissues to prevent adverse periodontal complications due to orthodontic forces [29]. With labial bodily movement there is a chance that the incisors develop apical migration of marginal gingiva [30]. Loss of connective tissue results in the presence of preexisting untreated gingival inflammation [31]. Therefore, there is a chance of gingival recession if the tooth movement is likely to result in reduction of soft tissue thickness [32]. Experimental studies have shown that as long as the tooth is moved within the alveolar process envelope, it is likely to result in minimal harmful side-effects on marginal soft tissues [33].

It has been found that thin, delicate tissues are more likely to undergo gingival recession than normal or thick tissues [34]. If the patient exhibits a minimal zone of attached gingiva or a thin tissue a free gingival graft placed before initiating any orthodontic treatment will help in enhancing tissues around the tooth & in controlling the inflammation [35]. Tooth extraction is usually indicated in patients with tooth size-arch length discrepancy [36].

Gingival invaginations which present as superficial changes in the shape of the gingiva occur in about 35% of cases after orthodontic space closure procedures [37, 38]. These vary from mild fissures in keratinized gingiva to deep clefts in the alveolar bone crossing interdental papilla either buccally or lingually through the alveolar bone [39]. Histological and histo-chemical specimens taken from gingival invagination sites demonstrate epithelial as well as the connective tissue hypertrophy and occasionally loss of gingival collagen [40]. The reason for the occurrence of these gingival invaginations is still unknown & requires further investigations. It could be due to the break-up in the continuity of the fibers within the gingiva, and also due to root movement [41]. It has also been proposed that gingival peeling could be one of the reasons for the formation of these invaginations [42].

Since these gingival invaginations could serve as potential sites for dental plaque accumulation, it has been considered as a potential risk factor for initiation of periodontal disorders during the course of orthodontic treatment [43]. Gingival recession has been one of the risk factors during the orthodontic treatment or after treatment completion & has been seen to occur more frequently with buccal tooth movement [44]. If teeth are being moved lingually, there is a chance that the gingival tissue will move coronally & become thicker [45]. It is generally advisable to monitor areas of thin gingival tissues during growth as the width of attached gingiva increases from mixed dentition to permanent dentition [46].

Upper and lower anterior teeth are most commonly affected by gingival recession during orthodontic treatment [47]. The relationship between orthodontic movements and gingival recession has been controversial in relation to tipping movements. Batenhorst *et al.* [48] found an association between gingival recession and orthodontic tipping tooth movements of the lower incisors in monkeys. However, other studies revealed no association between gingival recession or mucogingival defects after orthodontic tipping of the anterior teeth [49].

During surgical decompensation in skeletal class III cases, the lower incisors are intentionally proclined leading to gingival recession or formation of gingival clefts [50]. This possibility must be addressed during treatment planning and by undertaking sufficient care when executing the orthodontic treatment. Sometimes during orthodontic treatment; teeth with adequate gingiva develop localized recession. This is assumed to occur when forces applied exceed the reparative & remodeling capacity of alveolar bone. However it is more possible that the extent & direction of tooth movement might move the tooth through the cortical plate while the gingival attachment is free of inflammation

Example: when molar with wide divergent roots is moved into the space of narrow premolar alveolar zone.

EXTERNAL APICAL ROOT RESORPTION

External apical root resorption is the most common & frequent iatrogenic consequence of orthodontic treatment, although it might also occur in the absence of any orthodontic treatment.

The etiology, severity & degree of root resorption is multifactorial, involving both host & environmental factors. Or-

thodontically induced root resorption Fig. (8) starts adjacent to hyalinized zones and occurs during and after elimination of hyalinized tissues. Root resorption occurs when the pressure on the cementum exceeds its reparative capacity and dentin is exposed, allowing multinucleated odontoclasts to degrade the tooth substance. It has been shown that root resorption is highly correlated with longer treatment duration, fixed appliance treatment, individual susceptibility, orthodontic forces & the type of orthodontic tooth movement [51].

Microscopic changes which are difficult to detect on routine radiographic images appear on teeth roots. Root resorption causes root shortening & weakening of teeth arch [52]. Root resorption of greater than 1-2 mm is considered as clinically significant [53].

It has also been demonstrated that heavy forces are more likely to produce root resorption than light forces [54]. In a study conducted on the direction of force and tooth movement in the occurrence of root resorption, showed that compressive forces cause more resorption than tensile forces [55]. Another study showed that intrusion of teeth causes about four times more root resorption than extrusion. However extrusion of teeth might also lead to root resorption in susceptible individuals. Intrusive force together with lingual root torque & jiggling movement are correlated with significantly more root resorption [56, 57]. Segal *et al.* indicated that factors associated with the duration of active treatment might result in increase in apical root resorption & intrusive forces & total treatment duration are highly correlated with mean apical root resorption. They suggested that 2-3 months of pauses in active force which can be achieved with a passive archwire minimizes root resorption [58, 59]. Levander *et al.* showed that the amount of root resorption is significantly less in patients who are treated with pauses than in those treated with continuous forces [60].

Acaret *et al.* indicated that the application of intermittent forces results in less root resorption than does the application of continuous forces. This can be explained by the fact that a pause in the force allows the resorbed cementum to heal and prevents further resorption [61].

Among all teeth, maxillary incisors are most frequently involved in apical root resorption followed by mandibular incisors & first molars [62]. Remington *et al.* concluded that maxillary incisors are more frequently affected and to a more severe extent than the rest of the dentition [63].

Apical root resorption does not progress after active orthodontic treatment ends. Reparative processes in the form of smoothing & remodeling of sharp edges starts after cessation of treatment. Teeth with severely resorbed roots function in a reasonable manner & apical root resorption does not progress after orthodontic intervention [64].

Literature states that the apical part of the root has relatively minor importance for total periodontal support & approximately 3 mm of apical root loss is equivalent to 1 mm of crestal bone loss [65].

Tooth support is measured by the length of the root that is invested with in the alveolar bone. Loss of attached and crestal alveolar bone will reduce this support, so too will loss of root length by resorption.

Root Damage: Root resorption is usually seen in patients with fixed appliances affecting the apical 1-2 mm. Such resorption does not compromise on the long term health of the periodontium & the teeth [66]. More so ever, resorption where more than 1/3rd of root length is lost is rare & occurs in only 3% of the patients. Risk factors for increased incidence & severity of root resorption are the pretreatment root-form or root length, previous history of trauma to teeth, & treatment mechanics. Teeth with blunted roots are at increased risk of root resorption [67].

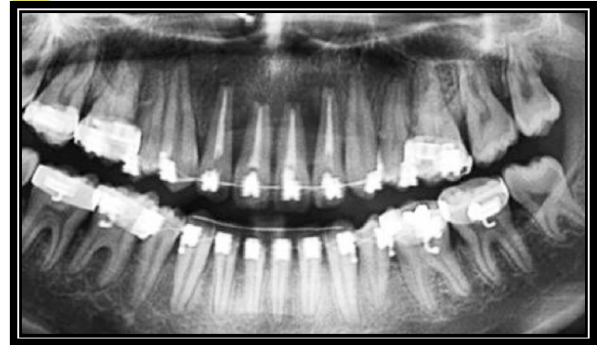


Fig. (8). Radiograph showing orthodontic-induced root resorption.

IATROGENIC DAMAGE FROM ELASTICS

Periodontal destruction due to use of elastic bands was firstly reported in the dentistry way back in 1980s. During different phases of orthodontic treatment, small elastics or rubber bands are used for generating a continuous force to achieve individual tooth movement. Elastics have long been used for the correction of orthodontic problems such as diastema, crossbites, and malposed teeth [68]. Elastics are also used for the intentional non-surgical removal of teeth in cases of hemophilia and also in patients treated with bisphosphonates, or some other anticoagulant medication [69, 70]. As a part of reducing the expenses, many patients choose the use of orthodontic rubber bands as a treatment option for closing diastemas [71]. But it is quiet common that the improper use of rubber bands can lead to severe periodontal destruction and tooth loss [72]. The periodontal destruction caused by orthodontic elastic bands could be iatrogenic [73]. There are only few published reviews of the literature and case studies in the recent years, reporting the effect of orthodontic elastic bands that are retained in the gingival tissues [74].

Periodontal lesions induced by elastic bands are complex to diagnose but have quite a few features in common that may assist in diagnosis and treatment. This could be due to the absence of local etiologic factors, lack of information gathered from the patients and no history of recent trauma or history of orthodontic treatment. Elastic rubber bands because of their elasticity, have a tendency to creep toward the narrower portion of the tooth and the roots, especially when there is no specific attachment mechanism [75]. As the band moves apically, it causes periodontal ligament destruction [76], resulting in extrusive movement of the tooth. The elastic band acts as a foreign body resulting in inflammatory reaction in the soft tissues, thereby weakening the periodontal attachments [77]. A study reported that the inflammatory reactions close to subgingivally extending rubber bands are

independent of the degree of plaque colonization [78]. Roots of the teeth taper towards the apex and a rubber band around the cervical area of two adjacent teeth will tend to move along the root surface, eventually causing a bloodless extraction of the teeth concerned [79].

Extraction

Orthodontic treatments that include extraction of dental units and movements of adjacent teeth in to the extraction sites can lead to attachment loss, bone loss, gingival clefts, gingival recession and root resorption.

Force

Teeth with adequate attached gingiva seldom develop gingival recession during orthodontic treatment. This may occur due to application of excessive forces which prevent the repair & remodeling of the alveolar bone.

Large forces which are produced by rapid palatal expansion have been shown to create a slight degree of attachment loss and some loss of alveolar bone height particularly in older patients. Excessive orthodontic force is also believed to increase risk of root resorption [80].

CONCLUSION

Apart from the benefits of orthodontic treatment like improvement in general & oral health, function, appearance, individual comfort & self esteem, the risks associated with its treatment are a reality. The complications associated with orthodontic treatment are a result of multifactorial process, with the patient, orthodontist & orthodontic appliances & procedures playing an vital role. A keen periodontal awareness should prevent or limit damage from the orthodontic treatment.

CONFLICT OF INTEREST

The authors confirm that this article content has no conflict of interest.

ACKNOWLEDGEMENTS

Declared none.

REFERENCES

- [1] Socransky SS, Haffajee AD. Evidence of bacterial etiology: a historical perspective. *Periodontol* 2000 1994; 5: 7-25.
- [2] Gong Y, Lu J, Ding X. Clinical, microbiologic and immunologic factors of orthodontic treatment-induced gingival enlargement. *Am J Orthod Dentofacial Orthod* 2011; 140(1): 58-64.
- [3] Teles R, Sakellari D, Teles F, Konstantinidis A, Kent R, Socransky S. Relationships among gingival crevicular fluid biomarkers, clinical parameters of periodontal disease, and the subgingivalmicrobiota. *J Periodontol* 2010; 81(1): 89-98.
- [4] Loe H, Theilade E, Jensen SB. Experimental gingivitis in man. *J Periodontol* 1965; 36: 177-87.
- [5] Naini FB, Gill DS. Tooth fracture associated with debonding a metal orthodontic bracket: a case report. *World J Orthod* 2008; 268: e32-6.
- [6] Ericsson I, Thilander B. Orthodontic forces and recurrence of periodontal disease: an experimental study in the dog. *Am J Orthod* 1978; 74: 41-50.

- [7] Ericsson I, Thilander B. Orthodontic relapse in dentitions with reduced periodontal support: an experimental study in dogs. *Eur J Orthod* 1980; 2: 51-7.
- [8] Ericsson I, Thilander B, Lindhe J, Okamoto H. The effect of orthodontic tilting movements on the periodontal tissues of infected and non-infected dentitions in dogs. *J Clin Periodontol* 1977; 4: 278-93.
- [9] Alfuriji S, Alhazmi N, Alhamlan N, Al-Ehaideb A, Alruwaithi M, Alkathheeri N, Geevarghese A. The Effect of Orthodontic Therapy on Periodontal Health: a review of the literature. *Int J Dent*. 2014, Article ID 585048, 1-8 pages.
- [10] Polson AM, Subtelny JD, Meitner SW, *et al*. Long-term periodontal status after orthodontic treatment. *Am J Orthod* 1988; 93: 51-8.
- [11] Boyd RL, Baumrind S. Periodontal implications of orthodontic treatment in adults with reduced or normal periodontal tissue versus those of adolescents. *Angle Orthod* 1992; 62: 117-26.
- [12] Zachrisson S, Zachrisson BU. Gingival condition associated with orthodontic treatment. *Angle Orthod* 1972; 42: 26-34.
- [13] Alexander SA. Effects of orthodontic attachments on the gingival health of permanent 2nd molars. *Am J Orthod Dentofacial Orthop* 1991; 100(4): 337-40.
- [14] Geisinger ML, Abou-Arraj RV, Souccar NM, Holmes CM, Geurs NC. Decision making in the treatment of patients with malocclusion and chronic periodontitis: scientific evidence and clinical experience. *Semin Orthod* 2014; 20(3): 170-6.
- [15] Sanders NL. Evidence-based care in orthodontics and periodontics: a review of the literature. *J Am Dent Assoc* 1999; 130: 521-7.
- [16] Eliasson LA, Hugoson A, Kurol J, Siwe H. The effects of orthodontic treatment on periodontal tissues in patients with reduced periodontal support. *Eur J Orthod* 1982; 4: 1-9.
- [17] Bagga DK. Adult Orthodontics Versus Adolescent Orthodontics: An Overview. *J Oral Health Comm Dent*. 2010; 4(2): 42-7.
- [18] Steffensen B, Storey AT. Orthodontic intrusive forces in the treatment of periodontally compromised incisors: a case report. *Int J Perio Rest Dent* 1993; 13: 433-41.
- [19] McComb JL. Orthodontic treatment and isolated gingival recession: a review. *Br J Orthod* 1994; 21: 151-9.
- [20] Mathews DP, Kokich VG. Managing treatment for the orthodontic patient with periodontal problems. *Semin Orthod* 1997; 3: 21-38.
- [21] Gartrell JG, Mathews DP. Gingival recession: the condition, process and treatment. *Dent Clin North Am* 1976; 1: 199-213.
- [22] Ko-Kimura N, Kimura-Hayashi M, Yamaguchi M, *et al*. Some factors associated with open gingival embrasures following orthodontic treatment. *Aust Orthod J* 2003; 19: 19-24.
- [23] Tarnow DP, Magner AW, Fletcher P. The effect of the distance from the contact point to the crest of bone on the presence or absence of the interproximal dental papilla. *J Periodontol* 1992; 63: 995-6.
- [24] Kurth JR, Kokich VG. Open gingival embrasures after orthodontic treatment in adults: prevalence and etiology. *Am J Orthod Dentofacial Orthop* 2001; 120: 116-23.
- [25] Kokich VO Jr, Kiyak HA, Shapiro PA. Comparing the perception of dentists and lay people to altered dental esthetics. *J Esthet Dent* 1999; 11: 311-24.
- [26] Reichert C, Hagner M, Jepsen S, Jäger A. Interfaces between orthodontic and periodontal treatment: their current status. *J Orofac Orthop* 2011; 72(3): 165-86.
- [27] Nokhbehsaim M, Deschner B, Winter J, *et al*. Contribution of orthodontic load to inflammation-mediated periodontal destruction. *J Orofac Orthop* 2010; 71(6): 390-402.
- [28] Zachrisson BU, Alnaes L. Periodontal conditions in orthodontically treated & untreated individuals. II. Alveolar bone loss. Radiographic findings. *Angle Orthod* 1974; 44: 48-55.
- [29] Dannan A. An update on periodontic - orthodontic interrelationships. *J Indian Soc Periodontol* 2010; 14: 66-71.
- [30] Dorfman HS. Mucogingival changes resulting from mandibular incisor tooth movement. *Am J Orthod* 1978; 74: 286-97.
- [31] Ericsson I, Thilander B, Lindhe J. Periodontal conditions after orthodontic tooth movements in the dog. *Angle Orthod*. 1978; 48(3): 210-218.
- [32] Coatoam GW, Behrens RG, Bissada NF. The width of keratinized gingiva during orthodontic treatment: its significance and impact on periodontal status. *J Periodontol* 1981; 52: 307-13.
- [33] Foushee DG, Moriarty JD, Simpson DM. Effects of mandibular orthognathic treatment on mucogingival tissues. *J Periodontol* 1985; 56: 727-33.

- [34] Maynard JG. The rationale for mucogingival therapy in the child and adolescent. *Int J Periodont Restorat Dent* 1987; 7: 36-51.
- [35] Meeran NA. Iatrogenic possibilities of orthodontic treatment and modalities of prevention. *J Orthod Sci* 2013; 2(3): 73-86.
- [36] Bolton WA. The clinical application of a tooth size analysis. *Am J Orthod* 1962; 48: 504-29.
- [37] Edwards JG. The prevention of relapse in extraction cases. *Am J Orthod* 1971; 60: 128-44.
- [38] Kuroi J, Ronnerman A, Heyden G. Long-term gingival conditions after orthodontic closure of extraction sites: histological and histochemical studies. *Eur J Orthod* 1982; 4: 87-92.
- [39] Rivera Circuns AL, Tulloch JF. Gingival invagination in extraction sites of orthodontic patients: their incidence, effects on periodontal health, and orthodontic treatment. *Am J Orthod* 1983; 83: 469-76.
- [40] Ronnerman A, Thilander B, Heyden G. Gingival tissue reactions to orthodontic closure of extraction sites: histologic and histochemical studies. *Am J Orthod* 1980; 77: 620-6.
- [41] Atherton JD. The gingival response to orthodontic tooth movement. *Am J Orthod* 1970; 58: 179-86.
- [42] Robertson PB, Schultz LD, Levy BM. Occurrence and distribution of interdental gingival clefts following orthodontic movement into bicuspid extraction sites. *J Periodontol* 1977; 48: 232-5.
- [43] Helm S, Petersen PE. Causal relation between malocclusion and periodontal health. *Acta Odontol Scand* 1989; 47: 223-8.
- [44] Steiner GG, Pearson JK, Ainamo J. Changes of the marginal periodontium as a result of labial tooth movement in monkeys. *J Periodontol* 1981; 52: 314-20.
- [45] Boyd RL. Mucogingival considerations and their relationship to orthodontics. *J Periodontol* 1978; 49: 67-76.
- [46] Sperry TP, Speidel TM, Isaacson RJ, Worms FW. The role of dental compensations in the orthodontic treatment of mandibular prognathism. *Angle Orthod* 1977; 47: 293-9.
- [47] Hall WB. The current status of mucogingival problems and their therapy. *J Periodontol* 1981; 52: 569-75.
- [48] Batenhorst KF, Bowers GM, Williams JE. Tissue changes resulting from facial tipping and extrusion of incisors in monkeys. *J Periodontol* 1974; 45: 660-68.
- [49] Allais D, Melsen B. Does labial movement of lower incisors influence the level of the gingival margin? A case-control study of adult orthodontic patients. *Eur J Orthod* 2003; 25: 343-52.
- [50] Dorfman HS. Mucogingival changes resulting from mandibular incisor tooth movement. *Am J Orthod* 1978; 74: 286-97.
- [51] Roscoe MG, Meira JBC, Cattaneo PM. Association of orthodontic force system and root resorption: a systematic review. *Am J Orthod Dentofac Orthop*. 2015; 147(5): 610-626.
- [52] Travess H. Orthodontics. Part 6: risks in orthodontic treatment. *Br Dent J* 2004; 196: 71-7.
- [53] Healey D. Rootresorption 2004. Available from: www.orthodontists.org.nz/root_resorption.htm
- [54] Jones AS, Darendeliler MA. Physical properties of root cementum: part 8. Volumetric analysis of root resorption craters after application of controlled intrusive light and heavy orthodontic forces: a microcomputed tomography scan study. *Am J Orthod Dentofac Orthop* 2006; 130: 639-47.
- [55] Chan E, Darendeliler MA. Physical properties of root cementum: part 7. Extent of root resorption under areas of compression and tension. *Am J Orthod Dentofac Orthop* 2006; 129: 504-10.
- [56] Han G, Huang S, Von den Hoff JW, Zeng X, Kuijpers-Jagtman AM. Root resorption after orthodontic intrusion and extrusion: an intraindividual study. *Angle Orthod* 2005; 75: 912-8.
- [57] Costopoulos G, Nanda R. An evaluation of root resorption incident to orthodontic intrusion. *Am J Orthod Dentofac Orthop* 1996; 109: 543-8.
- [58] Segal G, Shiffman P, Tuncay O. Meta analysis of the treatment related factors of external apical root resorption. *Orthod Craniofacial Res* 2004; 7: 71-8.
- [59] Mahida K, Agrawal C, Baswaraj H, Tandur AP, Patel B, Chokshi H. Root resorption: an abnormal consequence of the orthodontic treatment. *Int J Contemp Dent* 2015; 6: 7-9.
- [60] Levander E, Malmgren O, Eliasson S. Evaluation of root resorption in relation to two orthodontic treatment regimes. A clinical experimental study. *Eur J Orthod* 1994; 16: 223-8.
- [61] Acar A, Canyurek U, Kocaaga M, Erverdi N. Continuous vs. discontinuous force application and root resorption. *Angle Orthod* 1999; 69: 159-64.
- [62] Newman WG. Possible etiological factors in external root resorption. *Am J Orthod*. 1975; 67: 522-539.
- [63] Remington DN, Joondeph DR, Artun J, Riedel RA, Chapko MK. Long-term evaluation of root resorption occurring during orthodontic treatment. *Am J Orthod Dentofac Orthop* 1989; 96: 43-6.
- [64] Brezniak N, Wasserstein A. Root resorption after orthodontic treatment: Part 2. Literature review. 1993; 103(2): 138-146.
- [65] Weltman B, Vig KWL, Fields HW, Shanker S, Kaizer EE. Root resorption associated with orthodontic tooth movement: a systematic review. *Am J Orthod Dentofac Orthop* 2010; 137: 462-76.
- [66] Brezniak N, Wasserstein A. Root resorption after orthodontic treatment: Part 1. Literature review. *Am J Orthod Dentofac Orthop* 1993; 103: 62-6.
- [67] Linge BO, Linge L. Apical root resorption in upper anterior teeth. *Eur J Orthod* 1983; 5: 173-83.
- [68] Waggoner WF, Ray KD. Bone loss in the permanent dentition as a result of improper orthodontic elastic band use: a case report. *Quintessence Int* 1989; 20: 653-6.
- [69] Regev E, Lustmann J, Nashef R. Atraumatic teeth extraction in bisphosphonate-treated patients. *J Oral Maxillofac Surg* 2008; 66: 1157-61.
- [70] Spouge JD. Hemostasis in dentistry, with special reference to hemocoagulation. II. Principles underlying clinical hemostatic practices in normal patients. *Oral Surg Oral Med Oral Pathol* 1964; 18: 583-92.
- [71] Adcock JE. Exfoliation of maxillary central incisors due to misapplication of orthodontic rubber bands. *Tex Dent J* 1999; 116: 8-13.
- [72] Pan WL, Chan CP, Su C. Localized periodontitis induced by rubber bands. Report of two cases. *Changcheng Yi Xue Za Zhi* 1991; 14: 54-60.
- [73] Zilberman Y, Shteyer A, Azaz B. Iatrogenic exfoliation of teeth by the incorrect use of orthodontic elastic bands. *J Am Dent Assoc* 1976; 93: 89-93.
- [74] Vandersall DC, Varble DL. The missing orthodontic elastic band, a periodontic: orthodontic dilemma. *J Am Dent Assoc* 1978; 97: 661-3.
- [75] Olsen CB, Pollard AW. Severe bone loss caused by orthodontic rubber bands; management and nine-year follow-up: report of case. *ASDC J Dent Child* 1998; 65: 25-8.
- [76] Haralabakis NB, Tsianou A, Nicolopoulos C. Surgical intervention to prevent exfoliation of central incisors from elastic wear. *J Clin Orthod* 2006; 40: 51-4.
- [77] Al-Qutub MN. Orthodontic elastic band-induced periodontitis - a case report. *Saudi Dent J*. 2012; 24(1): 49-53.
- [78] Regev E, Lustmann J, Nashef R. Atraumatic teeth extraction in bisphosphonate-treated patients. *J Oral Maxillofac Surg* 2008; 66: 1157-61.
- [79] Zilberman Y, Shteyer A, Azaz B. Iatrogenic exfoliation of teeth by the incorrect use of orthodontic elastic bands. *J Am Dent Assoc* 1976; 93: 89-93.
- [80] Greenbaum KR, Zachrisson BU. The effect of palatal expansion therapy on the periodontal supporting tissues. *Am J Orthod* 1982; 81: 12-21.

Received: December 22, 2014

Revised: March 04, 2015

Accepted: March 10, 2015

© Rafiuddin et al.; licensee Bentham Open.

This is an open access article licensed under the terms of the Creative Commons Attribution Non-Commercial License (<http://creativecommons.org/licenses/by-nc/3.0/>) which permits unrestricted, non-commercial use, distribution and reproduction in any medium, provided the work is properly cited.