

Buccal Space Collection of Ozonized Sunflower Oil Following Off-Label Injection: A Case Report



Federico Berton¹, Matteo Zotti¹, Antonio Rapani¹, Roberto Di Lenarda¹ and Claudio Stacchi^{1,*} 

¹Department of Medical, Surgical and Health Sciences, University of Trieste, Trieste, Italy

Abstract:

Introduction: Ozonized sunflower oil is increasingly employed in the management of oral conditions due to its antimicrobial and immunostimulating properties. While topical use is generally considered safe, off-label applications, such as intrasulcular or periapical injections, may pose unexpected clinical risks. The aim of the present report was to describe an unusual complication due to an improper use of ozonated oil and its management.

Case Description: We, herein, report the case of a 67-year-old female presenting with facial swelling unresponsive to antibiotics and corticosteroids. Initial evaluation suggested an odontogenic abscess; however, ultrasonography revealed an irregular, avascular intramuscular collection with a surrounding hypoechoic halo. The patient disclosed prior treatment involving ozonized sunflower oil, raising suspicion of an inadvertent submucosal injection. Surgical drainage yielded brownish fluid, with microbiological analysis proving negative. A second aspiration was required due to residual swelling. The patient reported near-complete symptom resolution following the second intervention. This case highlighted the potential adverse outcomes of non-topical administration of ozonized oil, which is non-resorbable and may induce a foreign body inflammatory response. Ultrasonography played a key role in differential diagnosis and guided therapeutic intervention, which was successfully managed with needle aspiration.

Conclusion: Off-label injections of ozonized oil should be avoided. Ultrasound assessment is instrumental in diagnosis, and needle-driven aspiration may offer an effective, minimally invasive treatment.

Keywords: Ozonized sunflower oil, Oral surgery, Oral health, Granulomatous lesion, Ultrasound, Surgical drainage.

© 2025 The Author(s). Published by Bentham Open.

This is an open access article distributed under the terms of the Creative Commons Attribution 4.0 International Public License (CC-BY 4.0), a copy of which is available at: <https://creativecommons.org/licenses/by/4.0/legalcode>. This license permits unrestricted use, distribution, and reproduction in any medium, provided the original author and source are credited.

*Address correspondence to this author at the Department of Medical, Surgical and Health Sciences, University of Trieste, Trieste, Italy, S.C. Clinica di Chirurgia Maxillofacciale e Odontostomatologia, Ospedale Maggiore, Piazza dell'Ospitale 1, 34126, Trieste; Tel: +39 0403992020; E-mail: claudio@stacchi.it

Cite as: Berton F, Zotti M, Rapani A, Di Lenarda R, Stacchi C. Buccal Space Collection of Ozonized Sunflower Oil Following Off-Label Injection: A Case Report. Open Dent J, 2025; 19: e18742106408734. <http://dx.doi.org/10.2174/0118742106408734250919065345>



CrossMark

Received: April 20, 2025

Revised: June 24, 2025

Accepted: July 03, 2025

Published: October 07, 2025



Send Orders for Reprints to
reprints@benthamscience.net

1. INTRODUCTION

Ozone (O₃) is a triatomic allotrope of oxygen naturally present in the Earth's stratosphere, where it plays a critical role in shielding the planet from ultraviolet radiation. In medical applications, ozone is generated by passing pure oxygen through an electrical discharge, a process that produces a mixture of ozone and oxygen in various concentrations. Although ozone is highly reactive

and thus challenging to store and stabilize, its potent biological properties have attracted increasing interest in the biomedical field [1, 2].

Medically, ozone exhibits a broad spectrum of activity, including antimicrobial, antiviral, antifungal, and immunomodulatory effects. These effects are primarily attributed to its ability to generate reactive oxygen species (ROS) and lipid oxidation products, which can disrupt microbial

membranes and stimulate host immune responses [3-5]. Ozone therapy is considered a form of oxidative preconditioning, inducing mild oxidative stress that activates endogenous antioxidant pathways and modulates inflammatory processes [6, 7]. At controlled doses, this mechanism is exploited to promote wound healing, modulate local immune responses, and reduce microbial burden in infected tissues. However, the use of ozone is not without potential adverse effects. According to the World Federation of Ozone Therapy's Review on Evidence-Based Ozone Therapy, a safe concentration of 5-10 µg/mL is recommended for intralesional injections or irrigation procedures in order to minimize the risk of toxicity. Prolonged or excessive exposure to gaseous ozone may result in systemic symptoms, such as nausea, headache, and irritation of the upper respiratory tract [8-10].

In the dental field, ozone has gained recognition as an adjunctive treatment modality across a range of specialties. It has been used in the management of dental caries, endodontic disinfection, periodontal disease, alveolar osteitis, and mucosal lesions, such as recurrent aphthous stomatitis and oral lichen planus [11-14]. Its versatility is enhanced by the ability to deliver it in various forms, including ozone gas, ozonated water, and ozonized oils, allowing tailored application based on the clinical condition. Ozone therapy is also being explored as a complementary treatment for premalignant and malignant oral lesions due to its potential antimicrobial, anti-inflammatory, and immune-modulating properties, although scientific evidence on its effectiveness remains limited [15].

Ozonized oils, typically derived from sunflower or olive oil, are produced by reacting ozone with unsaturated fatty acids, forming stable ozonides. These compounds preserve the antimicrobial and anti-inflammatory properties of ozone while enabling safer and more controlled topical application [16, 17]. Ozonized sunflower oil, in particular, has emerged as a popular vehicle due to its higher linoleic acid content, offering a greater number of reactive sites for ozone binding, and demonstrating comparable germicidal effects to ozonized olive oil [18]. In periodontal therapy, the topical application of ozonized oil has been associated with reductions in clinical indices of inflammation and enhanced post-surgical healing. However, studies have also reported adverse outcomes, such as increased dentinal hypersensitivity, when ozonized oils have been introduced into periodontal pockets in certain contexts [19-22].

Despite the increasing adoption of ozonized oil in dental practice, its safety profile is well-established primarily for topical application. There is a paucity of data regarding its behavior when administered *via* off-label routes, particularly intratissue injection [23]. Ozonized oils are not water-soluble and, unlike gaseous ozone or ozonated water, are not readily metabolized or resorbed by host tissues. Consequently, inadvertent injection into the soft tissues or submucosal planes may result in foreign body-type granulomatous reactions, chronic inflammation, or persistent localized swelling due to the accumulation of non-resorbable material. In this context, herbal treatments, such as aloe vera, turmeric, and green tea extracts, may offer antimicrobial and anti-inflammatory effects and may serve

as safer alternatives to ozonized oil in managing localized oral lesions. Their biocompatibility and ability to support oral homeostasis make them promising options, though further clinical validation is needed [24].

This report presents a rare and previously undocumented complication arising from the off-label submucosal injection of ozonized sunflower oil, resulting in an intramuscular collection in the buccal space. The case underscores the diagnostic challenges posed by such presentations, which may mimic odontogenic infections, and emphasizes the role of imaging, particularly ultrasound, in guiding diagnosis and management. Moreover, it highlights the importance of recognizing the limitations of off-label therapeutic interventions with biologically active compounds, such as ozonized oils, which, despite their biocompatibility, may induce unintended tissue responses when used beyond approved indications.

2. CASE DESCRIPTION

A 67-year-old female patient with no significant medical history presented to the Maxillofacial and Stomatology Clinic at Trieste University Hospital, reporting swelling and pain on the left side of her face that began 14 days earlier (Fig. 1). The symptoms followed an unspecified treatment by her dentist, involving the topical application of an unknown substance around the upper left first molar. Subsequently, she underwent antibiotic (amoxicillin and clavulanic acid 1 gram three times a day for 2 weeks) and corticosteroid therapies, with no improvement in signs and symptoms. Extra-orally, the left middle-third region of the face resulted in swelling and presented a parenchymatous consistency, tenderness, and pain upon superficial palpation. On the intra-oral examination, the first superior left molar showed a 5 mm gingival recession on the palatal root, together with purulent drainage on gentle sulcular probing. Furthermore, no alteration in saliva quality and quantity from the Stensen duct was noted.

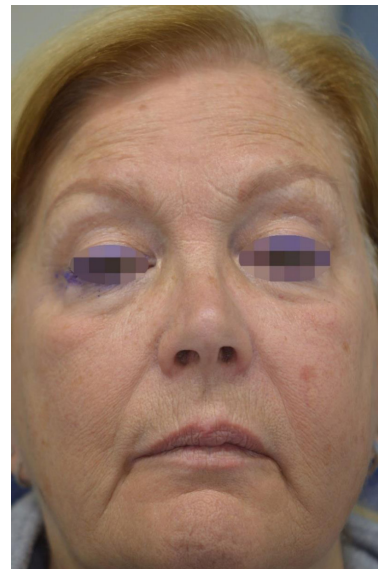

Fig. (1). Extraoral image of the patient showing swelling and edema in the left cheek region.

With the patient's consent, X-rays were performed. Orthopantomograms showed no macroscopic alteration of the bony structures, whereas an intraoral radiograph revealed a radiolucent apical lesion on tooth 2.6, suggesting a possible diagnosis of odontogenic abscess (Fig. 2). Therefore, a new antibiotic therapy (clindamycin 900 mg a day for 6 days) was prescribed, and an echography was scheduled for a more detailed evaluation of the swelling. The patient was re-evaluated three days later, showing no signs of improvement. The ultrasound showed a profound alteration in the intramuscular portion of the left cheek (buccal space), with a 3x2 cm central inhomogeneous portion with irregular and blurred edges. This central area was surrounded by a hyperechoic halo, suggesting a granulomatous reaction (Fig. 3). After further investigating the medical history and conducting an additional interview with the patient, it was found out that she had previously undergone a treatment with ozonized sunflower oil (Ozosan Gel, Bioactiva, Vicenza, Italy) used locally, after the use of anesthesia. Thus, the possibility of an off-label periapical injection of ozonized oil was considered. Only an injection administered coronal to the upper insertion of the buccinator muscle could explain the accumulation in the cheek.

In agreement with the patient, a surgical drainage was performed. After outlining the area of the collection with a dermatographic pencil (Fig. 4), a small incision (3 mm) was made in the mucosa anterior to the Stensen duct, and an

18-gauge needle was inserted. Compression of the cheek released a brownish liquid, which was aspirated (Fig. 5) and sent for microbiological analysis. Single interrupted resorbable stitches were applied [25]. Ten days later, due to the persistence of mild swelling, a second drainage was performed.

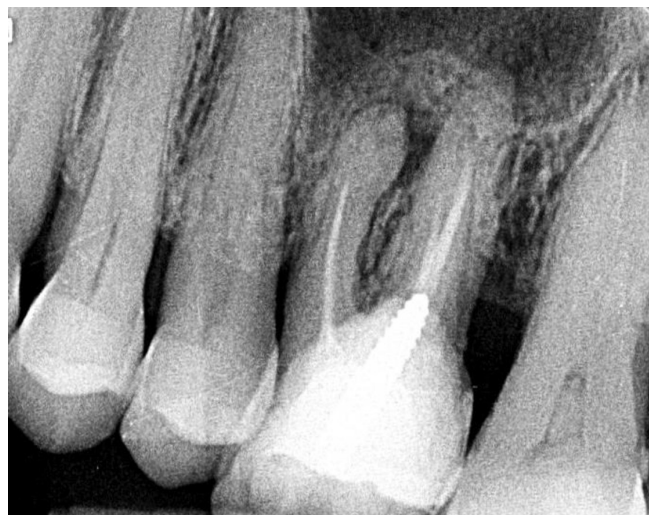

Fig. (2). Pre-operative periapical radiograph revealing a radiolucent apical lesion on tooth 2.6, suggesting a possible diagnosis of odontogenic abscess.

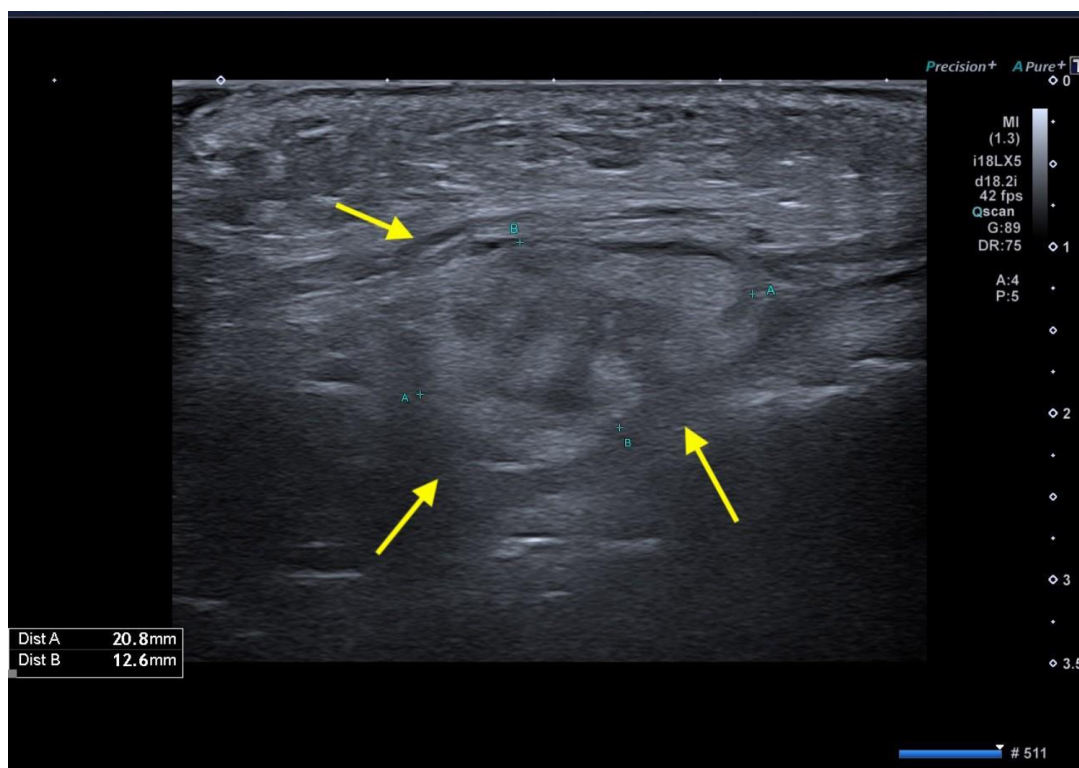


Fig. (3). Initial echography. The presence of a 3x2 cm central inhomogeneous portion with irregular and blurred edges, surrounded by a hyperechoic halo (yellow arrows), suggesting a granulomatous lesion.

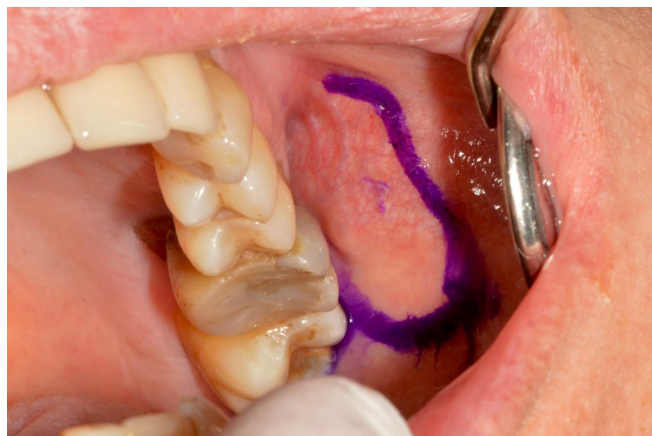

Fig. (4). The area of the collection was identified through palpation of the cheek and carefully marked using a dermographic pencil for precise localization.

During a 4-day check, the patient reported an almost complete resolution of symptoms, with no signs of inflammation or bleeding visible. A follow-up ultrasound was scheduled, and it revealed two anechoic areas (3 mm in diameter) and a blurred hyperechoic region in the sub-

cutaneous and muscular areas, with no clear boundaries (Fig. 6). Microbiological analysis resulted in negative findings, and facial asymmetry was no longer visible.

Two weeks later, the patient underwent the extraction of tooth 2.6. One month later, no symptoms were evident.

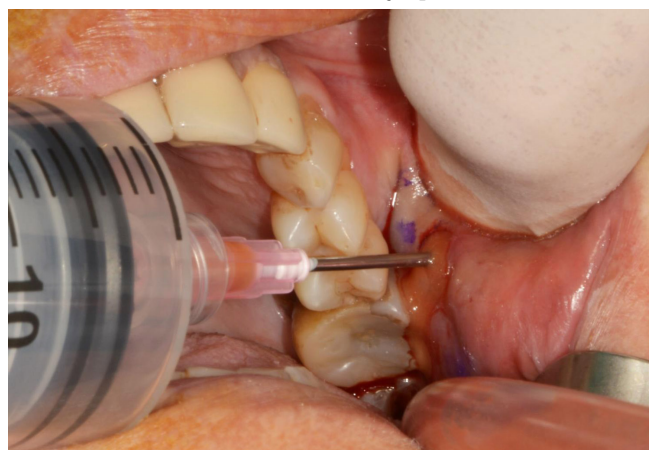


Fig. (5). Surgical drainage. Manual compression of the cheek resulted in the release of a brownish fluid, which was aspirated for analysis.

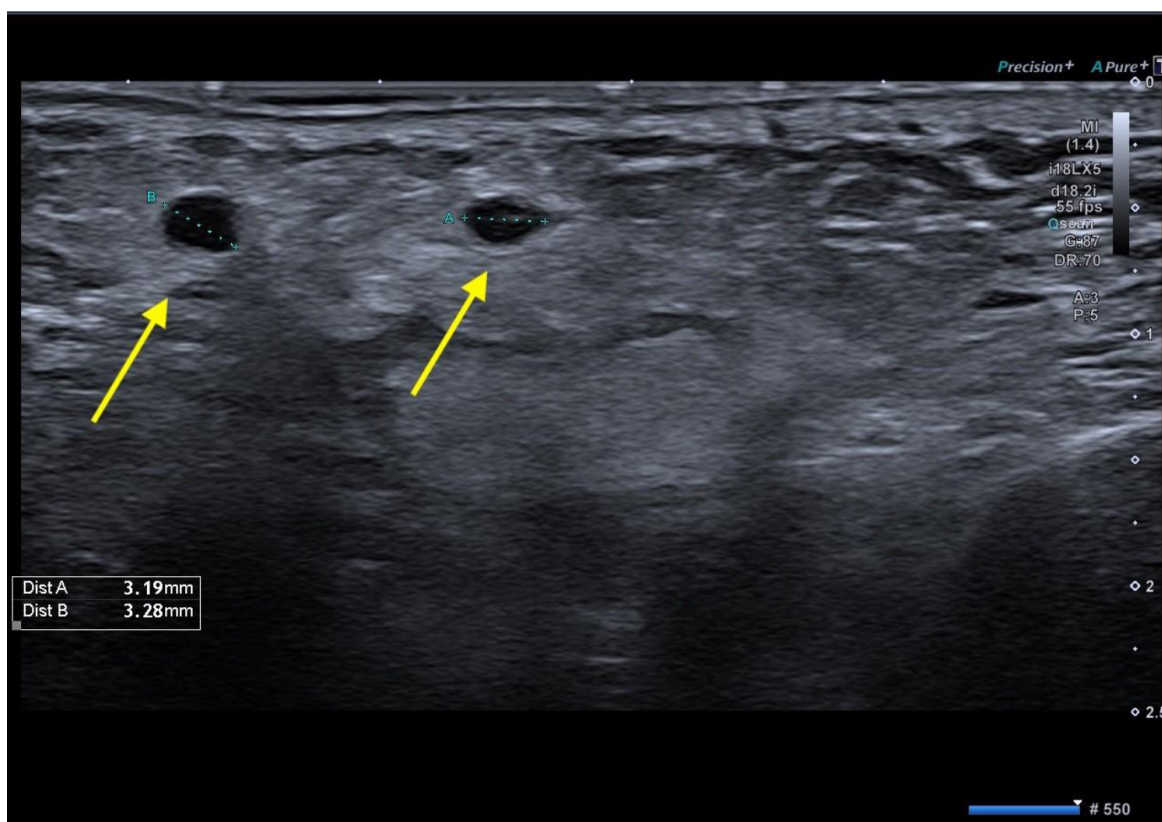


Fig. (6). Post-operative ultrasonography. Two small anechoic areas of approximately 3 mm in diameter were identified (yellow arrows), along with a poorly defined hyperechoic region within the subcutaneous and muscular tissues, lacking clear demarcation.

3. DISCUSSION

This case has illustrated an uncommon, but clinically significant complication associated with the off-label use of ozonized sunflower oil. While ozone has become increasingly popular in dentistry for its antimicrobial, anti-inflammatory, and tissue-regenerative effects [18], the therapeutic safety of its various formulations, particularly ozonized oils, depends heavily on the mode of administration [26-28]. As seen in this report, deviation from topical application, such as inadvertent or unintentional injection into soft tissue compartments, may provoke a foreign body reaction and chronic inflammation [29, 30].

The diagnostic challenge presented by this case lies in the clinical similarity between a foreign body granuloma and an odontogenic abscess. The patient's history of persistent facial swelling, coupled with lack of response to antibiotics and corticosteroids, initially pointed toward a resistant infection. Only after a more thorough anamnesis and imaging evaluation was the suspicion raised of a non-infectious inflammatory collection caused by ozonized oil. Given that ozonized sunflower oil is lipophilic and non-resorbable, it can persist in soft tissues and trigger localized immune responses, especially when injected unintentionally into deeper planes.

Ultrasonography played a central role in the differential diagnosis. The imaging revealed an irregular, avascular intramuscular collection with blurred margins and a surrounding hyperechoic halo, indicative of a granulomatous lesion. This is consistent with previously published findings in the field of cosmetic dermatology, where ultrasonography has been used to characterize complications from dermal fillers, especially non-resorbable materials [31]. The present case has provided support to the growing value of ultrasound in oral and maxillofacial diagnostics, not only for its non-invasive nature, but also for its ability to differentiate fluid collections, foreign materials, and abscesses with a high degree of accuracy [32].

The treatment strategy emphasized a minimally invasive approach. While traditional open surgical drainage was considered, a less traumatic needle aspiration was preferred to reduce morbidity. Although this initially achieved only partial resolution, a second aspiration proved effective. This has been found to align with best practices in managing similar filler-related lesions, where conservative management often precedes excisional intervention. The use of ultrasound-guided aspiration, although not performed in this case, has been well-documented in the context of oral cavity lesions [33], and could represent a valuable improvement, particularly in complex or recurrent presentations.

This case has also mirrored patterns observed in aesthetic medicine, where adverse tissue responses are frequently caused by the persistence of injected materials, such as silicone or even hyaluronic acid. A recent systematic review documented that over 87% of adverse reactions to injectable fillers occur due to foreign body responses [29], and more than half of the cases are associated with unapproved or impure materials, such as liquid silicone [30]. Although ozonized oils have not been

mentioned in these studies, the pathophysiological mechanisms appear similar, suggesting that any non-resorbable injectable substance can behave unpredictably when misplaced in soft tissues.

Furthermore, the importance of accurate clinical documentation and patient communication cannot be overstated. In this case, the lack of clarity surrounding the initial treatment and the absence of procedural details complicated the diagnostic process. This underlines the ethical and medico-legal implications of using alternative or off-label substances without sufficient documentation.

In summary, while ozonized sunflower oil remains a promising adjunctive therapy in dentistry, its safe use is contingent upon the appropriate route of administration. Misapplication, particularly through injection into non-target tissues, can result in unexpected and potentially protracted complications. Clinicians should be vigilant about the physical properties of therapeutic agents, especially those not designed for parenteral use. When complications arise, imaging modalities, such as ultrasonography, can be invaluable for diagnosis, treatment planning, and monitoring. This case reinforces the necessity of adhering to evidence-based protocols and raises awareness of a rare but relevant clinical scenario.

CONCLUSION

To date, no local adverse effects have been reported in the literature regarding the topical use of ozonized oil in dentistry. However, this case has demonstrated that off-label applications, particularly intratissue injections, may lead to significant complications due to the non-resorbable nature of the oil and its potential to elicit a foreign body inflammatory response. When such events occur, minimally invasive management through needle aspiration can offer a safe and effective therapeutic option. Moreover, ultrasonography has proven to be an essential diagnostic tool, enabling accurate differentiation from odontogenic infections and guiding appropriate treatment.

This case report has presented certain limitations that must be acknowledged. The lack of accurate documentation of the initial treatment required retrospective reconstruction of the patient's history, which may have introduced potential recall bias. Diagnosis relied solely on clinical and ultrasound findings, without histopathological confirmation to definitively characterize the lesion. Additionally, the aspiration procedure was conducted without real-time ultrasound guidance, which may have limited its precision and effectiveness. Furthermore, the limited follow-up did not allow for the assessment of possible long-term complications.

AUTHORS' CONTRIBUTIONS

The authors confirm their contribution to the paper as follows: F.B., C.S.: Study conception and design; M.Z.: Data collection; R.D.L.: Analysis and interpretation of results; A.R., F.B.: Drafting of the manuscript. All authors have reviewed the results and approved the final version of the manuscript.

ETHICS APPROVAL AND CONSENT TO PARTICIPATE

Not applicable.

HUMAN AND ANIMAL RIGHTS

Not applicable.

CONSENT FOR PUBLICATION

Informed consent was obtained for the study.

STANDARDS OF REPORTING

CARE guidelines were followed.

AVAILABILITY OF DATA AND MATERIALS

The data and supportive information are available within the article.

FUNDING

None.

CONFLICT OF INTEREST

Claudio Stacchi is the editorial advisory board member of the journal TODENTJ.

ACKNOWLEDGEMENTS

Declared none.

REFERENCES

- Elvis AM, Ekta JS. Ozone therapy: A clinical review. *J Nat Sci Biol Med* 2011; 2(1): 66-70.
<http://dx.doi.org/10.4103/0976-9668.82319> PMID: 22470237
- Clavo B, Borrelli E. Editorial: Ozone in medicine: Biochemical background, physiological modulation and clinical applications. *Front Physiol* 2023; 14: 1112860.
<http://dx.doi.org/10.3389/fphys.2023.1112860> PMID: 36814483
- Foroughi M, Khiadani M, Kakhki S, Kholghi V, Naderi K, Yektay S. Effect of ozonation-based disinfection methods on the removal of antibiotic resistant bacteria and resistance genes (ARB/ARGs) in water and wastewater treatment: A systematic review. *Sci Total Environ* 2022; 811: 151404.
<http://dx.doi.org/10.1016/j.scitotenv.2021.151404> PMID: 34767893
- Santos GM, Pacheco RL, Bussadori SK, *et al.* Effectiveness and safety of ozone therapy in dental caries treatment: systematic review and meta-analysis. *J Evid Based Dent Pract* 2020; 20(4): 101472.
<http://dx.doi.org/10.1016/j.jebdp.2020.101472> PMID: 33303100
- Celiberti P, Pazera P, Lussi A. The impact of ozone treatment on enamel physical properties. *Am J Dent* 2006; 19(1): 67-72. PMID: 16555661
- Huth KC, Saugel B, Jakob FM, *et al.* Effect of aqueous ozone on the NF-kappaB system. *J Dent Res* 2007; 86(5): 451-6.
<http://dx.doi.org/10.1177/154405910708600512> PMID: 17452567
- Chirumbolo S, Valdenassi L, Simonetti V, *et al.* Insights on the mechanisms of action of ozone in the medical therapy against COVID-19. *Int Immunopharmacol* 2021; 96: 107777.
<http://dx.doi.org/10.1016/j.intimp.2021.107777> PMID: 34020394
- Baysan A, Lynch E. The use of ozone in dentistry and medicine. Part 2. Ozone and root caries. *Prim Dent Care* 2006; os13(1): 37-41.
<http://dx.doi.org/10.1308/135576106775193897> PMID: 16393498
- Floare AD, Focht D, Hajdu AI, *et al.* Ozone and microstructural morphological changes of tooth enamel. *Rom J Morphol Embryol* 2023; 63(3): 539-44.
<http://dx.doi.org/10.47162/RJME.63.3.08> PMID: 36588492
- D'Amario M, Di Carlo M, Natale SM, *et al.* Application of ozone therapy in paediatric dentistry. *Appl Sci* 2022; 12(21): 11100.
<http://dx.doi.org/10.3390/app122111100>
- Kumar T, Arora N, Puri G, Aravinda K, Dixit A, Jatti D. Efficacy of ozonized olive oil in the management of oral lesions and conditions: A clinical trial. *Contemp Clin Dent* 2016; 7(1): 51-4.
<http://dx.doi.org/10.4103/0976-237X.177097> PMID: 27041901
- AL-Omiri MK, Alhijawi M, AlZarea BK, Abul Hassan RS, Lynch E. Ozone treatment of recurrent aphthous stomatitis: A double blinded study. *Sci Rep* 2016; 6(1): 27772.
<http://dx.doi.org/10.1038/srep27772> PMID: 27301301
- Torul D, Omezli MM, Avci T. Investigation of the clinical efficacy of CGF and ozone in the management of alveolar osteitis: A randomized controlled trial. *Clin Oral Investig* 2023; 27(8): 4521-9.
<http://dx.doi.org/10.1007/s00784-023-05074-3> PMID: 37231273
- Kogila AV, M K, K PR, Raju BHRK, Tyro D, Bhupathi A. A comparative study of pain and healing in post-dental extraction sockets treated with ozonated water/oil and normal saline. *J Maxillofac Oral Surg* 2022; 21(4): 1119-25.
<http://dx.doi.org/10.1007/s12663-020-01486-w> PMID: 36896071
- Ranjitha EG, Sridhar S, Deepthi A, Deepak JJH. Evaluating the efficacy of ozone therapy and low-level laser therapy in treating premalignant and malignant lesions: A systematic review. *J Pharm Bioallied Sci* 2024; 16: S4284-8. (Suppl. 5)
http://dx.doi.org/10.4103/jpbs.jpbs_897_24 PMID: 40061739
- Sechi LA, Lezcano I, Nunez N, *et al.* Antibacterial activity of ozonized sunflower oil (Oleozon). *J Appl Microbiol* 2001; 90(2): 279-84.
<http://dx.doi.org/10.1046/j.1365-2672.2001.01235.x> PMID: 11168731
- Kim SY, Lee JO, Lee S, *et al.* Ozonated sunflower oil (OSO) alleviates inflammatory responses in oxazolone-induced atopic dermatitis (AD)-like mice and LPS-treated RAW 264.7 cells. *J Microbiol Biotechnol* 2024; 34(4): 765-73.
<http://dx.doi.org/10.4014/jmb.2310.10037> PMID: 38247218
- Srikanth A, Sathish M, Sri Harsha A. Application of ozone in the treatment of periodontal disease. *J Pharm Bioallied Sci* 2013; 5(5): 89. (Suppl. 1)
<http://dx.doi.org/10.4103/0975-7406.113304> PMID: 23946585
- Nambiar S, Malothu S, Karmakar S, Varkey A, Chandra D, Chava VK. Comparison of ozonated olive oil and chlorhexidine gel as an adjunct to nonsurgical periodontal therapy for the treatment of chronic periodontitis: A randomized controlled clinical trial. *J Pharm Bioallied Sci* 2022; 14: S94-8. (Suppl. 1)
http://dx.doi.org/10.4103/jpbs.jpbs_565_21 PMID: 36110593
- Patel PV, Patel A, Kumar S, Holmes JC. Effect of subgingival application of topical ozonated olive oil in the treatment of chronic periodontitis: A randomized, controlled, double blind, clinical and microbiological study. *Minerva Stomatol* 2012; 61(9): 381-98. PMID: 22976566
- Gandhi KK, Cappetta EG, Pavaskar R. Effectiveness of the adjunctive use of ozone and chlorhexidine in patients with chronic periodontitis. *BDJ Open* 2019; 5(1): 17.
<http://dx.doi.org/10.1038/s41405-019-0025-9> PMID: 31814999
- Bilichodmath S, Deepthi R. Ozone therapy in periodontics: A meta-analysis. *Contemp Clin Dent* 2020; 11(2): 108-15.
http://dx.doi.org/10.4103/ccd.ccd_79_19 PMID: 33110321
- Mehrotra R, Gupta S, Siddiqui ZR, Chandra D, Ikbal SA. Clinical efficacy of ozonated water and photodynamic therapy in non-surgical management of chronic periodontitis: A clinico-microbial study. *Photodiagn Photodyn Ther* 2023; 44: 103749.
<http://dx.doi.org/10.1016/j.pdpdt.2023.103749> PMID: 37625764
- Kathayat G, Selvado DI, Erling Skalleveid H, *et al.* Natural oral care and herbal products for oral diseases and oral hygiene maintenance. *Pharmacological studies in natural oral care*. Beverly: Scrivener Publishing LLC 2023; pp. 47-59.
<http://dx.doi.org/10.1002/9781394167197.ch3>
- Stocco C, Berton F, Papa G, Bussani R, Arnez ZM. Vicryl

- hypersensitivity test with histological response. *Dermatitis* 2016; 27(3): 145-6.
<http://dx.doi.org/10.1097/DER.0000000000000182> PMID: 27172311
- [26] Leon BR, Romary DJ, Landsberger SA, Bradner KN, Ramirez M, Lubitz RM. Risks of ozonated oil and ozonated water on human skin: A systematic review. *Int Wound J* 2022; 19(7): 1901-10.
<http://dx.doi.org/10.1111/iwj.13760> PMID: 35083865
- [27] Díaz MF, Hernández R, Martínez G, *et al.* Comparative study of ozonized olive oil and ozonized sunflower oil. *J Braz Chem Soc* 2006; 17(2): 403-7.
<http://dx.doi.org/10.1590/S0103-50532006000200026>
- [28] Valacchi G, Fortino V, Bocci V. The dual action of ozone on the skin. *Br J Dermatol* 2005; 153(6): 1096-100.
<http://dx.doi.org/10.1111/j.1365-2133.2005.06939.x> PMID: 16307642
- [29] Machado R, Oliveira L, Martelli-Júnior H, *et al.* Adverse reactions to the injection of face and neck aesthetic filling materials: A systematic review. *Med Oral Patol Oral Cir Bucal* 2023; 28(3): e278-84.
<http://dx.doi.org/10.4317/medoral.25713> PMID: 36565218
- [30] Meire B P, Nilceo S M, Karime M H, Ediléia B, Sérgio T. A histologic study of adverse effects of different cosmetic skin fillers. *Skinmed* 2005; 4(6): 345-9.
<http://dx.doi.org/10.1111/j.1540-9740.2005.04061.x> PMID: 16276149
- [31] Wortsman X, Wortsman J, Orlandi C, Cardenas G, Sazunic I, Jemec GBE. Ultrasound detection and identification of cosmetic fillers in the skin. *J Eur Acad Dermatol Venereol* 2012; 26(3): 292-301.
<http://dx.doi.org/10.1111/j.1468-3083.2011.04047.x> PMID: 21418333
- [32] Rayudu NK, Palla S, Vaaka PHD, Rao DP. Impacted fish bone in buccal space associated with an abscess. *J Med Ultrasound* 2021; 29(1): 53-6.
http://dx.doi.org/10.4103/JMU.JMU_18_20 PMID: 34084718
- [33] Wei T, Lu M, Li J, *et al.* Comparative study on efficacy and safety of ultrasound guided transoral and transcutaneous core needle biopsy in patients with oral masses. *BMC Med Imaging* 2022; 22(1): 65.
<http://dx.doi.org/10.1186/s12880-022-00784-8> PMID: 35392835

DISCLAIMER: The above article has been published, as is, ahead-of-print, to provide early visibility but is not the final version. Major publication processes like copyediting, proofing, typesetting and further review are still to be done and may lead to changes in the final published version, if it is eventually published. All legal disclaimers that apply to the final published article also apply to this ahead-of-print version.