


The Open Dentistry Journal

Content list available at: <https://opendentistryjournal.com>



CASE REPORT

Digital Full-mouth Rehabilitation for Complex Cases Involving Severe Deep Overbite and Worn Dentition: A Case Report

Pooya Jannati¹ , Kelvin I. Afrashtehfar^{2,3,*} , Faranak Vakili¹  and Marzieh Alikhasi^{4,*} 

¹Department of Prosthodontics, School of Dentistry, Bandar Abbas University of Medical Sciences, Bandar Abbas, Iran

²Clinical Sciences Department, College of Dentistry, Ajman University, Ajman City, UAE

³Department of Reconstructive Dentistry & Gerodontology, School of Dental Medicine, University of Bern, Berne, Switzerland

⁴Dental Research Center, Dentistry Research Institute, Tehran University of Medical Sciences, Tehran, Iran

Abstract:

Introduction:

The demand for aesthetic restorations in dentistry has led to full-mouth reconstructions or rehabilitations (FMRs) as a viable solution for treating patients with worn and altered teeth. This study presents a clinical case report of a middle-aged patient with severe tooth wear and deep overbite with digital workflows.

Case Presentation:

The case report highlighted the successful application of digital technology in the comprehensive rehabilitation of a patient with worn dentition, showcasing improved esthetics, function, and patient comfort. The case report demonstrated the potential benefits of this rapid approach in achieving successful outcomes. Digital CAD/CAM technology is a solution for optimizing the prosthetic workflow, achieving time and cost efficiency, and delivering high-quality dental restorations.

Conclusion:

Future primary studies with larger sample sizes and longer follow-ups can further validate the FMR digital approaches.

Keywords: Tooth wear, Tooth erosion, Vertical dimension, Computer-aided design, Computer-aided manufacturing, Digital technology.

Article History

Received: May 19, 2023

Revised: July 24, 2023

Accepted: August 17, 2023

1. INTRODUCTION

Tooth wear is a phenomenon characterized by tooth surface loss (TSL) without bacterial infection and can have either physiological or pathological origins [1]. While physiological tooth wear occurs gradually with age, pathological wear, such as attrition, abrasion, abfraction, and erosion, is often multi-factorial in nature and can be challenging to isolate a single etiological factor in clinical presentations of worn dentition [2 - 4]. The term 'tooth surface loss' was proposed by Eccles in 1982 to encompass all causes of wear regardless of their identification [2 - 4]. Severe tooth wear can result in both esthetic and functional problems, including decreased vertical dimension of occlusion (VDO) [5].

* Address correspondence to these authors at the Artificial Center Research Center (AIRC), Ajman University, Ajman City, UAE; and at the Dental Research Center, Dentistry Research Institute, Tehran University of Medical Sciences, Tehran, Iran; E-mails: kelvin.afrahtehfar@unibe.ch (K.I.A.) and malikhasi@sina.tums.ac.ir (M.A.)

The management of worn dentition can range from preventive and localized treatments to full-mouth rehabilitation (FMR) based on the severity of the condition [6]. FMR presents a significant challenge for dental practitioners, requiring a reliable and predictable workflow. Integrating computer-aided design/computer-assisted manufacture (CAD/CAM) technology, advanced ceramic materials, and adhesive cementation offers a reliable approach to FMR [7, 8]. Conventional FMR techniques are often time-consuming, requiring numerous clinical appointments and laboratory procedures, with the risk of errors in each step potentially necessitating repeat treatment. Digital advances in intraoral scanners (IoS) and laboratory scanning, as well as intuitive software design, have greatly improved the speed and accuracy of CAD/CAM fabrication processes.

The use of virtual on-screen designing and CAM with rapid prototyping options such as milling (s-CAM) or printing (a-CAM) allows for the efficient production of various

restorations without physical models. The utilization of CAD/CAM technology enhances the predictability and reliability of FMR while reducing treatment duration and appointments/steps [9]. This clinical report outlines the application of a digital approach in a full-mouth rehabilitation procedure for a patient with severe deep bite occlusion and extensive tooth surface loss.

2. CLINICAL CASE REPORT

A 45-year-old male patient was referred to the Prosthodontics Department at the Dental College to treat his worn dentition. The patient presented with chief complaints of tooth surface loss (TSL), reduced chewing ability, and mild esthetic concerns, particularly regarding shade. The medical history was unremarkable, with no indications of temporomandibular joint disorder (TMD), except for excessive consumption of lemon and vinegar related to a pre-diabetes condition. Intraoral examination revealed a two-surface amalgam filling on the left second molar and composite resin fillings on the right first premolar, right second premolar, and right first molar. Abfraction was observed in several teeth of varying severity, with mild abfraction in all posterior teeth except for the right first and second molars, which showed moderate abfraction. The patient's occlusion was classified as Class II division 2 with a deep bite. All teeth displayed worn incisal/occlusal surfaces, exposing dentin in the maxillary central incisors, and limited to enamel in the maxillary premolars and most areas of the mandibular premolars (Fig. 1). The extraoral examination showed a square, symmetrical face, a slightly shorter lower third, and competent lips. The pattern of worn dentition did not match the opposing teeth, indicating that the cause of TSL was not solely due to parafunctional habits but may also have been a result of a chronic erosion progression exacerbated by job-related stress.

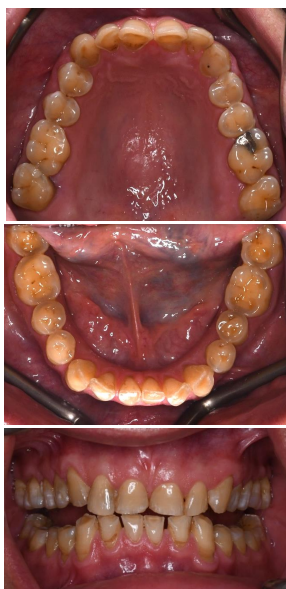

Fig. (1). Intraoral examination of the initial scenario displaying worn incisal/occlusal surfaces. (a) Maxillary arch (b), Mandibular arch (c), Exposed dentin in most incisal-labial and occlusal surfaces of mandibular teeth.

The incisal level of the mandibular anterior teeth was

adjusted using a flowable composite (G-aenial, GC, Tokyo, Japan), where the reference was the lip level (Fig. 2A). To analyze vertical dimension, phonetics, facial profile, and interocclusal space were evaluated. The vertical dimension of rest (VDR) was approximately 5 mm from the VDO. Lucia jig was made (GC Resin Pattern, GC, Japan). After several minutes and deprogramming of the muscles, the centric relation (CR) was recorded by injecting posterior bite registration (Granit, Mueller Omicron Dental, Lindlar, Germany) in the newly defined vertical dimension (VDR – VDO = 2). The first impressions were made using one-step putty/light-body silicon impression material (Speedex, Coltene, Altstätten, Switzerland), which served as a diagnostic cast. The ear-bow (Spring-bow Hanau earpiece facebow, WhipMixCorp, Kentucky, United States) record was determined for mounting on the Hanau semi-adjustable arcon articulator (Hanau Wide-Vue Arcon 183-2, WhipMixCorp, Kentucky).

Based on the earbow record, the maxillary cast was mounted on the articulator (Hanau Wide-Vue Arcon 183-2, WhipMix Corp, Kentucky, United States). Then, the mandibular cast was mounted against the maxillary cast using the jig and the CR record (Fig. 2B). The Broadrick flag was used to estimate the posterior plane on each side. The wax-up procedure was done based on the defined occlusal plane, and the putty index (Speedex, Coltene, Switzerland) was prepared intraorally for the mockup process.

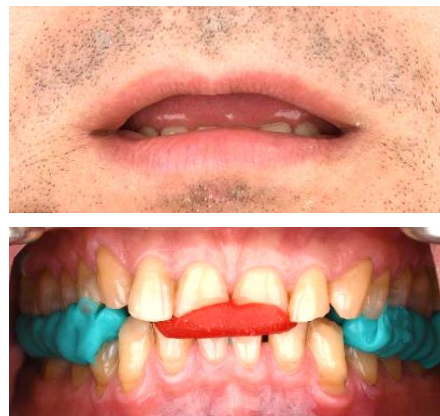

Fig. (2). (a) Lower incisal plane is mock-up with flowable composite and verified (b), Centric relation record using anterior jig.

The mockup was made with a bis-acrylic composite-based temporary material (Teco, Tecodental, New York). Face profile, smile, phonetics, and freeway space were examined after occlusal equilibration and adjustments, and minor esthetic modifications were made. Based on the mockup, the treatment planning was designed (full-coverage crowns: teeth #6, 7, 8, 9, 10, 11, and 28; laminate veneers: teeth #22, 23, 24, 25, 26, and 27; vonlay: teeth #4, 5, 12, and 13; overlay: teeth #3, 18, 19, 20, 21, 28, 29, and 30). Teeth #2, 14, and 15 were excluded from the treatment planning and were left intact since they provided stable holding contacts after a slight enameloplasty. Due to the presence of generalized TSL and the need to restore most posterior teeth to cover exposed dentin areas, establish stable occlusal contacts, create appropriate buffer space, and correct the deep curve of Spee, we were advised against utilizing the Dahl appliance. Despite being recognized as one

of the most conservative approaches in full-mouth rehabilitation (FMR), its application was cautioned against in this particular case [10]. The mockup was removed from the patient's mouth after he approved it, followed by finishing and polishing with discs (3M Sof-Lex, 3M, Minnesota, US). A flowable composite (G-aenial, GC, Tokyo, Japan) was used for cementing them as a temporary restoration for follow-up newly established VDO. Then, the patient's condition was assessed regarding the temporomandibular joint (TMJ) and muscle comfort, phonetics, chewing ability, and esthetics for four weeks.

The mockup of each jaw and the occlusion were scanned. The putty index was determined for tooth preparation. The anterior temporary restorations were removed. The maxillary and mandibular anterior tooth preparations were performed using a round-end cylindrical bur (Jota, Rüthi, Switzerland) based on the putty index. The occlusal clearance was assessed considering the posterior temporary restorations. After completing the anterior preparation, a new anterior jig was made as the anterior stop, maintaining the VDO. Retraction cords #00 (EasyCord, Mueller Omicron Dental, Lindlar, Germany) were used for gingival retraction for the crowns' and at the gingival vonlays' finish-line preparations. Both prepared arches and occlusion with the anterior jig were scanned with IoS (Medit i500, MEDIT Corp., Seoul, South Korea) (Fig. 3A).

The STL (Standard Tessellation Language) and PLY format (Polygon File Format) files were extracted and sent to the laboratory. The finish lines were determined. Then, the mockup, occlusion, and preparation STL files were superimposed on the corresponding prepared arch (Figs. 3B, 3C and 3D). These data were used to assess the final smile line using digital smile design (DSD) software (Digital smile design, Madrid, Spain). The restorations' shape and occlusal/incisal level were estimated and used for designing resin patterns (Detax, Ettlingen, Germany). Finally, resin patterns and Geller casts (Longer blue modeling resin, Longer3d, China) were printed (a-CAM) (Asiga, Sydney, Australia) (Figs. 3E and 3F).

Resin patterns were assessed intraorally. After verifying the adaptation and proximal contacts, occlusion adjustment was made in eccentric and centric movements. Face profile, smile line, phonetics, and freeway space were examined, and minor esthetic modifications were made with the patient's approval. Resins were sent to the laboratory to fabricate injectable resin patterns (Resione c01 transparent castable dental resin, Resione, Guangdong, China) and accomplish the heat-press process (Programate p3010, Ivoclar, Vaduz, Lichtenstein). The contouring process and staining (Ivoclar, Lichtenstein) on the Geller cast were done.

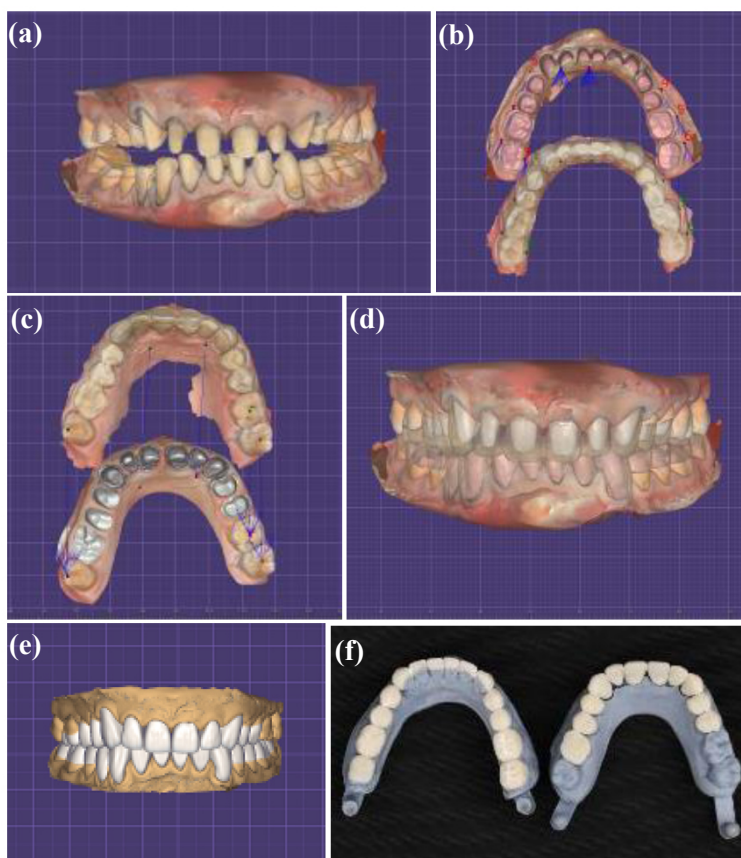


Fig. (3). (a) Preparation scan (b), Maxillary prepared teeth and temporary restorations superimposition, using anatomic landmarks (c), Mandibular prepared teeth and temporary restorations superimposition, using anatomic landmarks (d), Maxillary and mandibular superimposition (e), Resin patterns design (f), Resin patterns printed and ready to try-in.

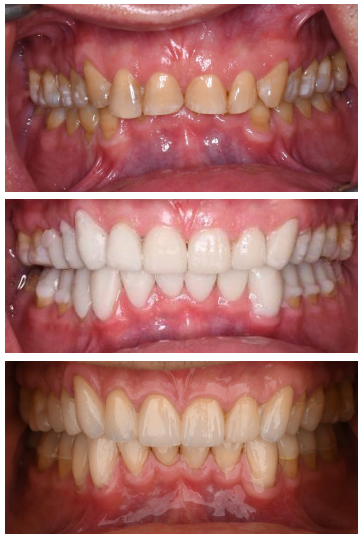

Fig. (4). (a) Intraoral frontal view of occlusion (before) (b), Intraoral frontal view of occlusion (resin patterns try-in) (c), Intraoral frontal view of occlusion (final restorations).

Pressed monolithic lithium disilicate glass-ceramic (Ivoclar, Lichtenstein) with a staining technique was chosen for all restorations. The A1 shade (VITA) was selected after consulting with the patient in standard light conditions and considering patient’s skin color and age. Based on the patient’s history and considering the comparative durability of dental ceramics, we decided against using direct composite resin, despite some studies advocating it as a conservative technique [11, 12].

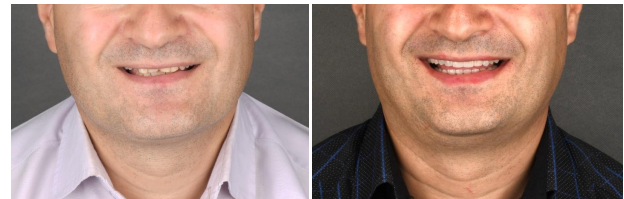


Fig. (5). (a) Smile view of patient profile (before) (b), Smile view of patient profile (after).

How can a full-mouth rehabilitation (FMR) be done in few appointments for complex patient cases with severe deep bite and extensive tooth loss?	
Materials and Methods	Findings
<p>A MEDLINE search was conducted in 2023.</p> <p>Limited to English language articles published from 2016 to 2022.</p> <p>Included reviews, guidelines, observational studies, and case reports/series.</p> <p>Selection done by two reviewers with disagreements resolved by a third.</p>	<p>Clinical evaluation and diagnosis of the patients dental condition.</p> <p>Develop a comprehensive treatment plan.</p> <p>Select monolithic lithium disilicate glass- ceramic restorations.</p> <p>Use digital workflows (CAD/CAM) for accurate and predictable fabrication.</p>
<p>Conclusion: FMRs of complex, severe tooth wear cases can be conservatively restored in 5 appointments thanks to the available digital technologies.</p>	<p>Reference: Jannati P, Afrashtehfar KI, Vakili F, Alikhasi M. Digital Full-Mouth Rehabilitation in Severely Overlapped and Worn Dentition: A Five-Session Approach for Complex Cases. <i>The Open Dentistry Journal</i> 2023.</p>

Fig. (6). Graphical abstract of the article.

After assessing the restorations’ adaptation, adjusting the proximal and occlusal contacts, and confirming the form and shade with the patient, the adjusted areas for restorations were finished and polished, and the cementation process started. The ceramics surface treatment was done with 20s hydrofluoric acid 5% (Porcelain Etchant, Bisco Schaumburg, IL, USA), 30s phosphoric acid 37%, (Etch-37, Bisco Schaumburg, IL, USA), and silane (Bis-Silane, Bisco Schaumburg, IL, USA), respectively. Under isolation with a rubber dam (Nic Ton, Bucharest, Hungary), surface treatment of the prepared tooth was done with pumice powder (Kemdent, Swidon, United Kingdom), Al₂O₃ air-abrasiion (Parkell, New York) (5s, 10mm, on exposed dentin), 20s phosphoric acid 37% (on enamel), 5th generation bonding (All-Bond3, Bisco

Schaumburg, IL, USA), and 6th generation dentine bonding agent (Clearfil SE BOND, Kuraray, Tokyo, Japan), respectively, for teeth with dominant enamel and dominant dentin. Considering the restoration thickness, the light-cure cement (Choise2 Trans, Bisco Schaumburg, IL, USA) was selected in the esthetic areas. A dual-cure cement (Duo-Link Universal, Bisco Schaumburg, IL, USA) was selected where the restorations were thicker (Figs. 4 and 5). The STL file of final restorations was used for stabilization appliance fabrication with clear resin (Detax, Ettlingen, Germany) and 3D printer (Asiga, Sydney, Australia) since there was no need to adjust the maxillary restoration during the occlusal equilibration.

3. DISCUSSION

This case report focused on the treatment procedure of a patient who suffered from pathologic deep overbite (*i.e.*, vertical overlap) and TSL in 5 appointments. Due to the presence of CAD/CAM technology for the clinician and technician, these cases can be treated in fewer sessions with more precise and predictive occlusion and esthetics [2, 13]. Patient's comfort, ease of making and restoring working casts, even Geller casts, superimposing details of confirmed mockup on prepared teeth, transferring the new determined VDO from mockup to final restorations precisely with minimum occlusal adjustments, facilitates the treatment procedure and results in fewer clinical and laboratory steps.

Obtaining esthetics in a monolithic restoration requires an experienced technician for detailed staining. The final shade and translucency of ceramic restorations can be significantly influenced by the type of material, cement, and substrate. In the present case, there was no discoloration in patient's teeth and a satisfying and vital final shade was obtained using translucent cement under monolithic restoration. From the perspective of color stability, lithium disilicate is less susceptible [14 - 17]. By this pathway, omitting porcelain layering steps and multiple and miscellaneous clinical try-in appointments, besides the optimal performance of monolithic restorations in an oral cavity environment, make way for quick treatment procedure (Fig. 6). Digital technology can reduce treatment errors by increasing the accuracy and predictability of treatment steps which lead to saving time [18 - 21]. Overall, digital CAD/CAM technology presents a promising solution for optimizing the prosthetic workflow, achieving time and cost efficiency, and delivering high-quality dental restorations.

CONCLUSION

The implementation of digital technology enables fast, conservative, and accurate restoration fabrication, yielding promising results. The present work demonstrates that utilizing a full arch digital workflow for designing and fabricating monolithic lithium disilicate glass-ceramic restorations is an effective treatment option for resolving severe deep overbite and tooth surface loss (Fig. 6).

LIST OF ABBREVIATIONS

FMRs	= Full-Mouth Reconstructions or Rehabilitations
TSL	= Tooth Surface Loss
VDO	= Vertical Dimension of Occlusion
CAD/CAM	= Computer-aided Design / Computer-assisted Manufac-ture
IoS	= Intraoral Scanner
TMD	= Temporomandibular Joint Disorder
CR	= Centric Relation

ETHICS APPROVAL AND CONSENT TO PARTICIPATE

Not applicable.

HUMAN AND ANIMAL RIGHTS

Not applicable.

CONSENT FOR PUBLICATION

Informed consent was obtained from the patient.

STANDARDS OF REPORTING

CARE guidelines were followed.

AVAILABILITY OF DATA AND MATERIALS

The data that support the discussion of this work are available from the corresponding authors, [M.A. and K.I.A.], upon reasonable request.

FUNDING

None.

CONFLICT OF INTEREST

The authors declare no conflict of interest, financial or otherwise.

ACKNOWLEDGEMENTS

Declared none.

REFERENCES

- [1] Joda T, Zarone F, Ferrari M. The complete digital workflow in fixed prosthodontics: A systematic review. *BMC Oral Health* 2017; 17(1): 124. [<http://dx.doi.org/10.1186/s12903-017-0415-0>] [PMID: 28927393]
- [2] Hashemi AM, Hashemi HM, Siadat H, Shamschiri A, Afrashtehfar KI, Alikhasi M. Fully digital *versus* conventional workflows for fabricating posterior three-unit implant-supported reconstructions: A prospective crossover clinical trial. *Int J Environ Res Public Health* 2022; 19(18): 11456. [<http://dx.doi.org/10.3390/ijerph191811456>] [PMID: 36141729]
- [3] Joda T, Brägger U. Digital vs. conventional implant prosthetic workflows: A cost/time analysis. *Clin Oral Implants Res* 2015; 26(12): 1430-5. [<http://dx.doi.org/10.1111/clr.12476>] [PMID: 25179680]
- [4] Pan S, Guo D, Zhou Y, Jung RE, Hämmerle CHF, Mühlemann S. Time efficiency and quality of outcomes in a model-free digital workflow using digital impression immediately after implant placement: A double-blind self-controlled clinical trial. *Clin Oral Implants Res* 2019; 30(7): 617-26. [<http://dx.doi.org/10.1111/clr.13447>] [PMID: 31021451]
- [5] Joda T, Brägger U. Time-efficiency analysis of the treatment with monolithic implant crowns in a digital workflow: A randomized controlled trial. *Clin Oral Implants Res* 2016; 27(11): 1401-6. [<http://dx.doi.org/10.1111/clr.12753>] [PMID: 27796072]
- [6] Joda T, Katsoulis J, Brägger U. Clinical fitting and adjustment time for implant-supported crowns comparing digital and conventional workflows. *Clin Implant Dent Relat Res* 2016; 18(5): 946-54. [<http://dx.doi.org/10.1111/cid.12377>] [PMID: 26395013]
- [7] Mühlemann S, Benic GI, Fehmer V, Hämmerle CHF, Sailer I. Randomized controlled clinical trial of digital and conventional workflows for the fabrication of zirconia-ceramic posterior fixed partial dentures. Part II: Time efficiency of CAD-CAM *versus* conventional laboratory procedures. *J Prosthet Dent* 2019; 121(2): 252-7. [<http://dx.doi.org/10.1016/j.prosdent.2018.04.020>] [PMID: 30037692]
- [8] de Oliveira NRC, Pigozzo MN, Sesma N, Laganá DC. Clinical efficiency and patient preference of digital and conventional workflow for single implant crowns using immediate and regular digital impression: A meta-analysis. *Clin Oral Implants Res* 2020; 31(8): 669-86. [<http://dx.doi.org/10.1111/clr.13604>] [PMID: 32329094]

- [9] Bishti S, Tuna T, Rittich A, Wolfart S. Patient-reported outcome measures (PROMs) of implant-supported reconstructions using digital workflows: A systematic review and meta-analysis. *Clin Oral Implants Res* 2021; 32(S21): 318-35. [http://dx.doi.org/10.1111/clr.13846] [PMID: 34642981]
- [10] Poyser NJ, Porter RWJ, Briggs P F A, Chana HS, Kelleher MGD. The Dahl Concept: Past, present and future. *Br Dent J* 2005; 198(11): 669-76. [http://dx.doi.org/10.1038/sj.bdj.4812371] [PMID: 15951771]
- [11] Burian G, Erdelt K, Schweiger J, Keul C, Edelhoff D, Güth JF. In-vivo-wear in composite and ceramic full mouth rehabilitations over 3 years. *Sci Rep* 2021; 11(1): 14056. [http://dx.doi.org/10.1038/s41598-021-93425-z] [PMID: 34234225]
- [12] Edelhoff D, Erdelt KJ, Stawarczyk B, Liebermann A. Pressable lithium disilicate ceramic *versus* CAD / CAM resin composite restorations in patients with moderate to severe tooth wear: Clinical observations up to 13 years. *J Esthet Restor Dent* 2023; 35(1): 116-28. [http://dx.doi.org/10.1111/jerd.12947] [PMID: 35919964]
- [13] Ioannidis A, Bomze D, Hämmerle CHF, Hüsler J, Birrer O, Mühlemann S. Load-bearing capacity of CAD/CAM 3D-printed zirconia, CAD/CAM milled zirconia, and heat-pressed lithium disilicate ultra-thin occlusal veneers on molars. *Dent Mater* 2020; 36(4): e109-16. [http://dx.doi.org/10.1016/j.dental.2020.01.016] [PMID: 31992483]
- [14] Jurado CA, Afrashtehfar KI, Hyer J, Alhotan A. Effect of sintering on the translucency of CAD–CAM lithium disilicate restorations: A comparative *in vitro* study. *J Prosthodont* 2023; jopr.13644. [http://dx.doi.org/10.1111/jopr.13644] [PMID: 36609993]
- [15] Shirani M, Emami M, Mosharraf R, Savabi O, Akhavanhaleghi M, Azadbakht K. Comparing the color match of monolithic CAD–CAM dental ceramics with the VITA Classical shade guide. *J Prosthet Dent* 2022; •••: S0022-3913(22)00463-2. [http://dx.doi.org/10.1016/j.prosdent.2022.06.024] [PMID: 36115709]
- [16] Jurado CA, Amarillas-Gastelum C, Afrashtehfar KI, Argueta-Figueroa L, Fischer NG, Alshabib A. Ceramic and composite polishing systems for milled lithium disilicate restorative materials: A 2D and 3D comparative *in vitro* study. *Materials (Basel)* 2022; 15(15): 5402. [http://dx.doi.org/10.3390/ma15155402] [PMID: 35955341]
- [17] Jurado CA, Amarillas-Gastelum C, Tonin BSH, Nielson G, Afrashtehfar KI, Fischer NG. Traditional *versus* conservative endodontic access impact on fracture resistance of chairside CAD–CAM lithium disilicate anterior crowns: An *in vitro* study. *J Prosthodont* 2022; jopr.13625. [http://dx.doi.org/10.1111/jopr.13625] [PMID: 36471494]
- [18] Ergun G, Yucel AS. Full-mouth rehabilitation of a patient with severe deep bite: A clinical report. *J Prosthodont* 2014; 23(5): 406-11. [http://dx.doi.org/10.1111/jopr.12113] [PMID: 24393501]
- [19] Afrashtehfar KI, Weber A, Abou-Ayash S. Titanium-base abutments may have similar long-term peri-implant effects as non-bonded one-piece abutments. *Evid Based Dent* 2022; 23(4): 134-5. [http://dx.doi.org/10.1038/s41432-022-0835-9] [PMID: 36526831]
- [20] Jurado CA, Sadid-Zadeh R, Watanabe H, *et al.* Effect of incisal preparation design on the fracture strength of monolithic zirconia-reinforced lithium silicate laminate veneers. *J Prosthodont* 2023; jopr.13689. [http://dx.doi.org/10.1111/jopr.13689] [PMID: 37014263]
- [21] Afrashtehfar K, Alnakeb NA, Assery MKM. Accuracy of intraoral scanners *versus* traditional impressions: A rapid umbrella review. *J Evid Based Dent Pract* 2022; 22(3): 101719. [http://dx.doi.org/10.1016/j.jebdp.2022.101719] [PMID: 36162879]