



The Open Dentistry Journal

Content list available at: <https://opendentistryjournal.com>



RESEARCH ARTICLE

A Cone-Beam Computed Tomography (CBCT) Study of Root Anatomy, Canal Morphology and Bilateral Symmetry of Permanent Maxillary Premolar Teeth Among the Qatari Subpopulation

Hanan Diab^{1,*}, Fatima Al-Sheeb¹, Amal Diab¹, Nadya Marouf¹, Maryam Al Obaid¹ and Mashaël Lari¹

¹Department of Dentistry, Oral Health Institute, Hamad Medical Corporation, Doha, Qatar

Abstract:

Objectives:

The study aims to evaluate the root anatomy, canal morphology, and symmetry of maxillary premolars teeth in a Qatari subpopulation using cone-beam computed tomography (CBCT).

Materials and Methods:

544 CBCT images of Qatari patients were analyzed by two endodontists. Tooth position, number of roots, canal configuration, and number of canals per root were investigated. A chi-square test was used to evaluate the association between gender and the number of roots. The interexaminer and intraexaminer were performed and documented.

Results:

The most common root anatomy and canal morphology observed in maxillary first premolars (MFP) were two roots (70.6%) with a single canal per root, while in maxillary second premolars (MSP), there was one root (84.3%) with a single canal (83%).

Type I Vertucci morphology was predominated in all roots of two-rooted MFP (97%), three-rooted MFP (100%), single-rooted MSP (42%), and two-rooted MSP (100%). The Chi-square test showed an association between gender and number of roots in both MFP and MSP, with a higher number of roots seen in men ($P < 0.05$).

A symmetrical pattern was observed in the number of roots and canals in both maxillary premolars. But the symmetry for the type of canal configuration is higher in MFP (78%) than MSP (54%).

Conclusion:

In the Qatari subpopulation, most MFP had two roots with a predominance of type I Vertucci, while MSP had one root with type I. Contralateral MSP showed more diversity in canal configuration that should be considered during root canal treatment. CBCT is an effective diagnostic tool to investigate root anatomy and canal morphology.

Keywords: Maxillary premolars, Root anatomy, Canal morphology, Cone beam computed tomography, Symmetry, Chi-square test.

Article History

Received: November 28, 2021

Revised: February 9, 2022

Accepted: March 9, 2022

1. INTRODUCTION

Identifying root anatomy and canal morphology, which is considered to be ethnically and genetically determined, is essential for successful endodontic treatment [1]. It has been found that incorrect identification of the morphology or the number of the roots and canals is the second-most significant

cause of treatment failure after wrong diagnosis and treatment planning [2].

The morphology of permanent maxillary premolars has been widely reported within the literature as complex [3, 4] and can be found in all eight different types of canal morphology and root canal anatomy [5]. These variations lead to considerable challenges for the dentist during endodontic treatment. Furthermore, permanent maxillary premolars are considered the second most endodontically treated teeth after the maxillary first molars [6, 7].

* Address correspondence to this author at the Department of Dentistry, Oral Health Institute, Hamad Medical Corporation, Doha, Qatar;
E-mail: hdiab@hamad.qa

Cone-beam computed tomography (CBCT) is a useful technology to study root anatomy and root morphology, as it reflects the 3-dimensional evaluation of root and canal morphology. Many *in vivo* studies have demonstrated the benefit of using CBCT in identifying the complexity of the root canal system [8].

Many classifications have been used to describe root canal morphology in the literature, including the Weine [9], Pindea [3], Vertucci [5, 10] and Gulabivala [11]. Vertucci [10] has classified root canals into eight categories, which have been widely used by many investigators.

To date, no previous studies have investigated the root canal system in maxillary premolars among the Qatari subpopulation. Thus, this study explores the root anatomy and canal configuration of permanent maxillary premolar teeth in the Qatari subpopulation using CBCT.

2. MATERIALS AND METHODS

2.1. Selection of the Sample

The protection of human subjects was carefully considered in this study. Data was collected retrospectively from patients' records. The study did not require dealing directly with human subjects. Patients' personal information, such as names and personal identification numbers, were not collected because they were not required; codes have been used instead. Anonymity was preserved during all study phases. All data had been appropriately destroyed when the study was completed. Furthermore, this retrospective descriptive study was performed with the approval of the Medical Research Centre (MRC) and the Institutional Review Board (IRB) at Hamad Medical Corporation (HMC) (Approval #17228/17), which carefully reviewed the protection of human subjects before providing their approval.

Five hundred forty-four CBCT images of Qatari patients were analyzed in this study who attended Hamad Dental Services (Hamad Dental Centre, Al Wakrah Hospital, and Al Khor Hospital) between 2014 and 2016 for different treatment purposes.

The teeth were selected according to the following inclusion criteria: (1) Permanent teeth with fully developed roots; (2) No intracanal or extra radicular restorations; (3) No apical lesions; (4) Canals without calcification or resorption; (5) Clear CBCT images with no distortion. When one of these criteria was not fit, the teeth were excluded, and the reasons for exclusion were documented.

2.2. Cone-Beam Computed Tomography:

CBCT images were taken using a D-CAT scanner (Imaging Sciences International, Hatfield, PA, USA) operated at 120 KVp(eff) tube voltage, 20 mA tube current with 14.7s scanning time, 0.4 to 0.2 mm voxel size, and a field of view of 160 mm x 40 mm. After the acquisition, data was transferred to Infinitt Dental PACS (Infinitt Healthcare, Seoul, South Korea) as DICOM files, and these files were not anonymized, exported with the patient's data.

2.3. Image Investigation:

The CBCT images were inspected by two endodontists (N.M and A.D) who had at least 10 years of experience, independently. During the examination, the reviewers were instructed to view the images through the sagittal, coronal, and axial views. Magnification, enhancement, and brightness were applied when needed using the Infinitt software (Infinitt Healthcare, Seoul, South Korea, version 11.4) and Xelis Dental 3D Viewer software (Seoul, South Korea, version 1.0) to extract the required information. To calculate interexaminer and intraexaminer agreement, 20% of the images were evaluated by each viewer alone and twice in a three weeks intervals.

Data about the age and gender of the patient; inclusion or exclusion and the reason for exclusion; type and location of the tooth; the number of roots and canals in each root; canal type according to Vertucci classification [5] were recorded. Any root canal configuration with a different classification from those presented by Vertucci was documented as 'other'. Any incidental findings such as the presence of anatomical variations and congenital anomalies or pathologic changes were documented as well.

The number of roots was analyzed from the axial plan of CBCT image, according to Pecora *et al.* [12], single-rooted teeth: teeth with a single or fused root despite the number of canals; double-rooted: teeth with two roots regardless they were complete or partial; three-rooted: teeth with three separated roots at any position along with buccal or palatal roots.

2.4. Statistical Analysis

The statistical analysis was processed using Statistical Product and Service Solutions (SPSS) version 20 (SPSS Inc, Chicago, IL). A descriptive analysis was used to record the characteristics of the root anatomy and root canal configuration of the permanent teeth, including frequency, percentages, mean, and standard deviation.

A chi-square test was used to evaluate the relationship between gender and the number of roots. A Kappa agreement analysis was performed to calculate the interexaminer and intraexaminer agreement between the raters.

3. RESULTS

A total of 544 CBCT records were evaluated. The interexaminer agreement result was 93.9% (range 89.1% to 98.7%), and the intraexaminer agreement was 91.7% (range 87.4% to 98.1%).

3.1. Maxillary First Premolars (MFP)

A total of 442 (40.6%) maxillary first premolars were included in this study of 1088 teeth. Most of MFP were from female patients (62.7%) when compared to male patients (37.3%). The average age was 35.7 years, ranging from 11 to 79 (Table 1).

Table 1. Demographic Characteristics of patients with maxillary first and second premolars (no: n number, % percentage, MFP: maxillary first premolars, MSP: maxillary second premolars).

	Number of teeth Included	Number of teeth excluded	Left	Right	Female	Male	Age Mean	Age standard Deviation	Age Median
MFP no (%)	442 (40.6)	646 (59.4)	222 (50.2)	220 (49.8)	277 (62.7)	165 (37.3)	35.67	16.3 (11-79)	34
MSP no (%)	408 (37.5)	680 (62.5)	208 (51)	200 (49)	252.0 (61.8)	156.0 (38.2)	34.1	16.3	32

3.1.1. Root anatomy

The number of roots observed in MFP was two (70.6%). Single and three roots were also observed in 26.9% and 2.4%, respectively (Table 2). In relation to gender, higher percentages of two-rooted MFP were observed in males (81.8%) than females (63.9%), while no significant difference was reported between the genders in three-rooted MFP with a P-value of 0.485 (Table 3).

3.1.2. Root Canal Morphology

In single-rooted MFP, the prevalence of a single canal was

50.4% and the prevalence of two canals was 49.6% (Table 2). The most common root canal configuration in the single-rooted MFP is type II (25%), followed by type IV (22.7%), type III (21%), and type I (20.2%). Other classifications such as type V, VI, (7.6%, 1.6% respectively) were also observed in single-rooted MFP in lesser quantities (Table 4).

In two-rooted MFP, root canal configuration was found to be mainly type I in both buccal and palatal roots (BI, PI) in 97% of the sample. The other variations found include Buccal type III Vertucci classification combined with palatal type I Vertucci classification (BIII, PI) in 1%, (BV, PI) in 0.3%, (BVII, PI) in 0.3%, and (B1, PV) in 0.3% (Table 4).

Table 2. Number of roots and canals in maxillary first and second premolars (no: number, % percentage, MFP: Maxillary First Premolars, MSP: Maxillary Second Premolars).

Number of roots	Single-Rooted		Double-Rooted	Three-Rooted
	1 Canal	2 Canals	2 Canals	3 Canals
MFP no (%) Total: 442	60 (50.4)	59 (49.6)	312 (100)	11 (100)
MSP no (%) Total:408	287 (83)	57 (16)	64 (100)	0 (0)

Table 3. Number and percentage of roots according to gender in MFP and MSP (no: number, % percentage, MFP: Maxillary First Premolars, MSP: Maxillary Second Premolars).

Number of roots	MFP			MSP	
	One Root	Two Roots	Three Roots	One Root	Two Roots
Female no (%)	92 (33.2%)	177 (63.9%)	8 (2.9%)	228 (90.5%)	24 (9.5%)
Male no (%)	27 (16.4%)	135 (81.8%)	3 (1.8%)	116 (74.4%)	40 (25.6%)
P-value	0.0001	0.0001	0.485	<0.0001	<0.0001

Table 4. Root canal morphology of maxillary first (MFP) and second (MSP) premolars to Vertucci *et al.* [5] classification (no: number, % percentage, B: Buccal, P: Palatal, MB: Mesiobuccal, DB: Distobuccal).

Single- rooted							
Vertucci classification	I	II	III	IV	V	VI	other
MFP no (%)	24 (20.2)	30 (25)	25 (21)	27 (22.7)	9 (7.6)	2(1.6)	2(1.6)
MSP no (%)	147 (42)	30 (8.7)	93 (27)	20 (5.8)	44 (12.7)	6 (1.7)	4 (1.1)
Double- rooted Three- rooted							
Vertucci classification	BI, PI	BIII, PI	BV, PI	BVII, PI	B1, PV	MBI, DBI, PI	

(Table 4) contd....

MFP no (%)	304 (97)	5 (1)	1 (0.3)	1(0.3)	1 (0.3)	11 (100)
MSP no (%)	64 (100)	0 (0)	0 (0)	0 (0)	0 (0)	0 (0)

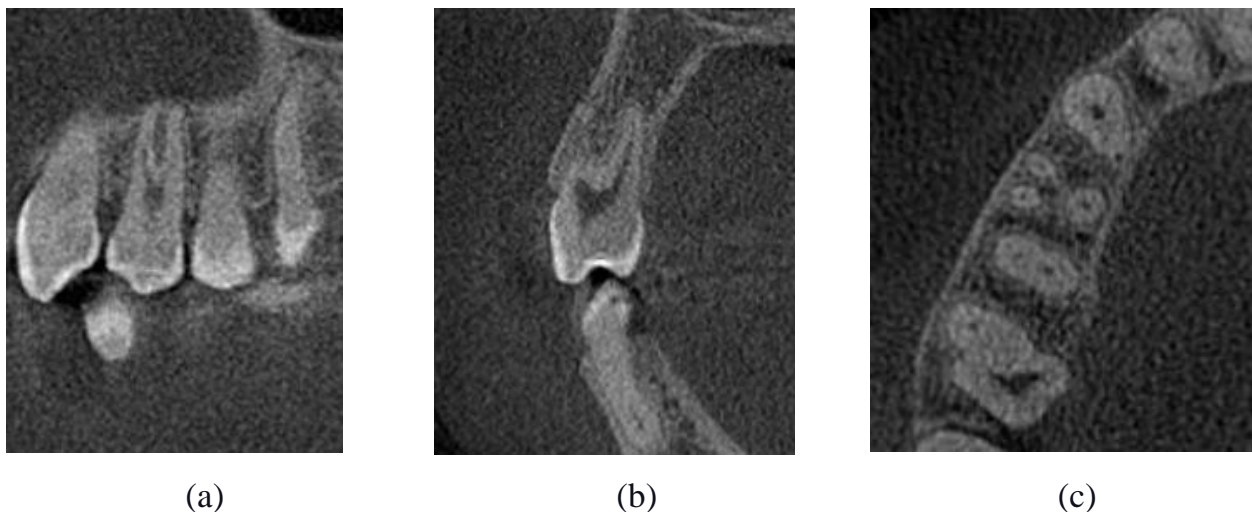


Fig. (1). Maxillary right first premolar with three roots:(a) sagittal view, (b) coronal view, (c) axial view.

In three-rooted MFP, type I Vertucci classification was observed for all the roots, mesiobuccal, distobuccal, and palatal (MBI, DBI, PI) 100% (Fig. 1).

3.1.3. Root and Canal Symmetry

A total of 137 (83.5%) of 164 patients had symmetrical roots between the right (RT) and left (LF) MFP. Out of the 137 patients with symmetrical roots, 106 (77.3%) patients had 2 roots, 27 (19.7%) patients had 1 root and 4 (2.9%) patients had 3 roots.

A total of 134 (81.7%) of 164 patients had a symmetrical number of canals per root C/R. 106 Of these, 79.1% had one canal in each root, one canal in the buccal, and one canal in the palatal root (B1, P1). Thirteen (9.7%) patients had a single canal in a single root (C1/ R1). Eleven (8.2%) patients had two canals in a single root (C2/R1) and four (2.9%) patients with three roots had a single canal in each root (MB1, DB1, P1). The root canal configuration was found to be symmetrical in 128 of 164 patients (78%). One hundred and two of them had Vertucci classification type I in buccal and palatal roots.

3.2. Maxillary Second Premolars (MSP)

The number of maxillary second premolars included in this study was 408 teeth out of 1088 (37.5%). Female patients represented 252 of the teeth (61%) compared to 156 (38.2%) teeth from male patients. The average age of the patients included in the analysis was 34.1 years, ranging from 12 to 79 (Table 1).

3.2.1. Root Anatomy

In MSP, the number of roots most commonly observed was single root in 84.3% of the teeth.

Two-rooted MSP were only observed in 15.7% of the teeth (Table 2). In relation to gender, higher percentages of two-rooted MSP were observed in males (25.6%) than Females (9.5%), while the single root was predominant in both sexes (Table 3).

3.2.2. Root Canal Morphology

In single-rooted MSP, the prevalence of a single canal was 83%, and the prevalence of two canals was only 16% (Table 2). The most common root canal configuration in single-rooted MSP was a type I (42%), followed by type III (27%), type V (12.7%), type V (12.7%), and type II (8.7%). Other classifications such as type IV, VI, and VII (5.8%, 1.7%, 1.1%) were also observed in single-rooted MSP, although these occurred in fewer teeth (Table 4).

In the two-rooted MSP, type I Vertucci classification was only found in each root (BI, PI) (Table 4).

3.2.3. Root and Canal Symmetry

One hundred thirty-four (88.2%) of the 152 patients had a symmetrical number of roots between the right (RT) and left (LF) MSP. Out of the 134 patients with symmetrical roots, 120 (89%) had a single root and 14 (10.1%) had two roots.

Out of 152 patients, 119 (78%) had a symmetrical number of canals per root C/R. Of which, ninety-five patients (79%) had a single root with a single canal (C1/R1), while 10 patients (8%) had a single root with two canals (C2/R1). Fourteen patients (11%) had a single canal in each root, one canal in the buccal, and one in the palatal (B1, P1). The root canal configuration was found to be symmetrical in 83 patients (54.6%). Thirty-eight patients (45%) had Vertucci classification type I in the right (RT) and left (LF) MSP and 16 patients (19%) had type III.

4. DISCUSSION

To complete successful root canal therapy, dentists need to have a comprehension understanding of the root morphology and canal complexity [1]. As the complexity of internal canal morphology increases in premolar teeth, the occurrence of endodontic procedural errors and apical pathosis increases as well [13]. This study investigated the root anatomy, root canal morphology, and symmetry of maxillary premolars in the Qatari subpopulation using CBCT.

4.1. Maxillary First Premolars (MFP)

In the current study, the majority of MFP had two roots in 70.6% of the cases; this was similar to many studies conducted in different populations in America [4, 14], Andalusia [15], Turkey [16], Jordan [17], Spain [15, 18], Saudi Arabia [19, 20], Germany [21], Russia [22], Brazil [23] and Pakistan [24]. However, other studies reported a higher prevalence of single-rooted MFP than two-rooted, such as in the Chinese [25, 26], Brazilian [12], and Indian [27, 28] populations.

The three-rooted MFP was observed in 11% of our sample. This is following previous reports [15, 21, 29] that showed a percentage of 9% and higher. On the contrary, some studies reported incredibly low incidents, which range from 0% to 6 [4, 12, 14, 16 - 19, 23, 26, 28, 30 - 32]. The discrepancies in the results of these studies might be attributed to differences in the ethnic group, methodology, sample size, variance in interpretation, and resolution between CBCT and other techniques used.

As a result, MFP with two roots might be associated with challenges during tooth extraction, orthodontic movement, and endodontic treatment. Therefore, the endodontist should extend the access cavity thoroughly to avoid missing the palatal root in two-rooted teeth and be aware that there is a possibility of three roots during access preparation.

All observed two-rooted MFP, was with two canals; this is in line with other studies [3, 4, 33] that reported a high prevalence of two canals in MFP, ranging between 73.3% to 92%.

Different types of Vertucci classification were observed for the single-rooted MFP, compared to two- and three-rooted MFP. As a result, the endodontist should never underestimate the complex canal anatomy of these single-rooted teeth. However, other studies [14, 18, 20, 21, 23, 34 - 36] have reported that type IV is more frequent in MFP.

In comparison with a single-rooted MFP, type I was the only configuration investigated in three-rooted MFP, and the same type predominates in the MFP with two roots (97%) which disagree with others [14] who have reported that type III is more in two-rooted MFP and type VI in three-rooted MFP.

4.2. Maxillary Second Premolars (MSP)

According to the current study, most MSP was from a single root (84%). Similar results, which are 80% and more have been reported in other studies [12, 18, 23, 24, 27, 37].

No incident was identified for the MSP with three roots in the Qatari population, although other studies [16, 18, 38] have

reported incidents of three roots but in small numbers. The prevalence of a single canal in MSP is high (83%) in this paper. This is consistent with previous findings such as [20, 35, 39], but it contrasts with other studies that found two canals frequently occur in the MSP [16, 21, 40].

The most common Vertucci classification observed in single and two-rooted MSP was a type I, this is in agreement with other studies that have reported the same root canal configuration [10, 16, 18, 20, 23, 34, 37]. On the other hand, type IV [35, 36, 38, 40] and type V (2-1) [40, 21] have been reported in the literature.

4.3. Symmetry

Few studies have investigated the degree of symmetry in root canal morphology in contralateral premolars [25, 41, 42]. Johnsen *et al.* [42] found a high prevalence of general symmetry between mandibular and maxillary premolars. In contrast to other studies [43], a low prevalence of symmetry between premolar teeth has been reported. Tian *et al.*, 2012 [25] investigated canal configuration in a small sample of CBCT images for MFP, and reported 64% of bilateral similarities. However, this discrepancy might be attributed to the variation in the methodology and sample size in these studies.

In the present study, bilateral MFP teeth had a symmetrical pattern in the number of roots/canals and types of canal configuration. These results were similar to the study by Y.-h. Li *et al.* [39] who identified symmetry among MFP in the root and canal numbers by 80% and 72% in root canal configuration.

In comparison with MSP, bilateral symmetry was high among the number of roots, and the number of canals per root, but drops to (54%) for the types of canal configuration. This result was quite different from studies in a Chinese population [39] that have been reported the bilateral symmetry in the type of canal configuration is much higher (73.3%).

MFP was found to be more symmetrical than MSP in the root canal configuration, compared to other studies, such as Y.-h. Li *et al.* [39], reported that anatomical similarities are greater for MSP than MFP. Similarly, Felsypremila *et al.* [41] showed the same percentage of symmetry between maxillary first (81.5%) and second (81.5%) premolars.

4.4. Gender and Number of Roots

In the present study, the Chi-square test ($P < 0.05$) showed a significant association between gender and the number of roots in both MFP and MSP, with a higher number of two roots in male than female patients (Table 3). Similar results have been reported among the Portuguese population [44]. However, other studies have investigated no association between the number of roots and sex [18, 20].

4.5. Limitations

This paper is not without limitations. CBCT can be considered a diagnostic tool to study root canal anatomy and root canal morphology, although when compared to micro-CT images, micro-CT can provide a higher resolution and more

detailed information on the external and internal anatomy of the teeth [40]. However, CBCT is suitable for clinical uses. Moreover, the voxel size used in the current study may not be ideal for endodontic assessment, as CBCT records were taken for different treatment purposes, not exclusively for endodontic reasons, and collected retrospectively to avoid radiation exposure.

Furthermore, this study was based on Vertucci classification, which does not address the number or configuration of the root(s) in maxillary premolars [45], and many unidentified anatomical configurations have been reported [46]. However, Vertucci's classification is widely used by many investigators, which means the results in the current study can be compared with other reports.

Future studies could be conducted with a bigger sample size by using a noninvasive, three-dimensional imaging system based on the Standardized Protocol for reporting root and canal anatomy [47]. In addition, a new coding system could be used [45] to describe root canal anatomy more accurately and overcome the limitations of other classification systems.

CONCLUSION

This study showed the most common root anatomy and canal morphology of MFP were two roots with a predominance of type I Verticucci classification, and one root with type I in MSP in the Qatari subpopulation. A higher degree of bilateral symmetry was reported in the MFP than in the MSP in the root canal configuration

ETHICS APPROVAL AND CONSENT TO PARTICIPATE

This retrospective descriptive study was performed with the approval of the Medical Research Centre (MRC) and the Institutional Review Board (IRB) at Hamad Medical Corporation (HMC) (Approval #17228/17), which was carefully reviewed the protection of human subjects before providing their approval.

HUMAN AND ANIMAL RIGHTS

No Animals were used in this research. All human research procedures were followed in accordance with the ethical standards of the committee responsible for human experimentation (institutional and national), and with the Helsinki Declaration of 1975, as revised in 2013.

STANDARDS FOR REPORTING

STROBE guidelines and methodologies were followed in this study.

CONSENT FOR PUBLICATION

Consent was not required for this type of study. The data was anonymized and deidentified before the analysis

AVAILABILITY OF DATA AND MATERIALS

The CBCT images data used to support the findings of this study are restricted by and the Institutional Review Board (IRB) at Hamad Medical Corporation (HMC) to protect

patients' privacy.

FUNDING

This work was financially supported by the Medical Research Centre (MRC) and the Institutional Review Board (IRB) at Hamad Medical Corporation (HMC). The funding body had no role in the study design, data collection, and decision to publish or preparation of the manuscript.

CONFLICT OF INTEREST

The authors declare that they have no known competing financial interests or personal relationships that could have appeared to influence the work reported in this paper.

ACKNOWLEDGMENTS

The authors would like to thank Dr. Tharupeedikayil S.Shailaja, Dr. Nayla Obaidan, and Dr.Khalid Al-haithami for their valuable contribution to this study.

REFERENCES

- Vertucci FJ. Root canal morphology and its relationship to endodontic procedures. *Endod Topics* 2005; 10: 3-29. [<http://dx.doi.org/10.1111/j.1601-1546.2005.00129.x>]
- Hargreaves Kenneth M, Berman Louis H. Cohen's Pathways of the Pulp. 2016.
- Pineda F, Kuttler Y. Mesiodistal and buccolingual roentgenographic investigation of 7,275 root canals. *Oral Surg Oral Med Oral Pathol* 1972; 33(1): 101-10. [[http://dx.doi.org/10.1016/0030-4220\(72\)90214-9](http://dx.doi.org/10.1016/0030-4220(72)90214-9)] [PMID: 4500261]
- Carns EJ, Skidmore AE. Configurations and deviations of root canals of maxillary first premolars. *Oral Surg Oral Med Oral Pathol* 1973; 36(6): 880-6. [[http://dx.doi.org/10.1016/0030-4220\(73\)90340-X](http://dx.doi.org/10.1016/0030-4220(73)90340-X)] [PMID: 4524838]
- Vertucci FJ. Root canal anatomy of the human permanent teeth. *Oral Surg Oral Med Oral Pathol* 1984; 58(5): 589-99. [[http://dx.doi.org/10.1016/0030-4220\(84\)90085-9](http://dx.doi.org/10.1016/0030-4220(84)90085-9)] [PMID: 6595621]
- Slowey RR. Root canal anatomy. Road map to successful endodontics. *Dent Clin North Am* 1979; 23(4): 555-73. [PMID: 294389]
- Zaatar EI, al-Kandari AM, Alhomaidah S, al-Yasin IM. Frequency of endodontic treatment in Kuwait: Radiographic evaluation of 846 endodontically treated teeth. *J Endod* 1997; 23(7): 453-6. [[http://dx.doi.org/10.1016/S0099-2399\(97\)80302-0](http://dx.doi.org/10.1016/S0099-2399(97)80302-0)] [PMID: 9587301]
- Patel S, Brown J, Pimentel T, Kelly RD, Abella F, Durack C. Cone beam computed tomography in Endodontics - A review of the literature. *Int Endod J* 2019; 52(8): 1138-52. [<http://dx.doi.org/10.1111/iej.13115>] [PMID: 30868610]
- Weine FS, Healey HJ, Gerstein H, Evanson L. Canal configuration in the mesiobuccal root of the maxillary first molar and its endodontic significance. *Oral Surg Oral Med Oral Pathol* 1969; 28(3): 419-25. [[http://dx.doi.org/10.1016/0030-4220\(69\)90237-0](http://dx.doi.org/10.1016/0030-4220(69)90237-0)] [PMID: 5257186]
- Vertucci F, Seelig A, Gillis R. Root canal morphology of the human maxillary second premolar. *Oral Surg Oral Med Oral Pathol* 1974; 38(3): 456-64. [[http://dx.doi.org/10.1016/0030-4220\(74\)90374-0](http://dx.doi.org/10.1016/0030-4220(74)90374-0)] [PMID: 4528716]
- Gulabivala K, Aung TH, Alavi A, Ng YL. Root and canal morphology of Burmese mandibular molars. *Int Endod J* 2001; 34(5): 359-70. [<http://dx.doi.org/10.1046/j.1365-2591.2001.00399.x>] [PMID: 11482719]
- Pécora JD, Saquy PC, Sousa Neto MD, Woelfel JB. Root form and canal anatomy of maxillary first premolars. *Braz Dent J* 1992; 2(2): 87-94. [PMID: 1290917]
- Nascimento EHL, Nascimento MCC, Gaêta-Araujo H, Fontenele RC, Freitas DQ. Root canal configuration and its relation with endodontic technical errors in premolar teeth: A CBCT analysis. *Int Endod J* 2019; 52(10): 1410-6. [<http://dx.doi.org/10.1111/iej.13158>] [PMID: 3111507]
- Vertucci FJ, Gegauff A. Root canal morphology of the maxillary first premolar. *J Am Dent Assoc* 1979; 99(2): 194-8.

- [15] [\[http://dx.doi.org/10.14219/jada.archive.1979.0255\]](http://dx.doi.org/10.14219/jada.archive.1979.0255) [PMID: 287737] Chaparro AJ, Segura JJ, Guerrero E, Jiménez-Rubio A, Murillo C, Feito JJ. Number of roots and canals in maxillary first premolars: Study of an Andalusian population. *Endod Dent Traumatol* 1999; 15(2): 65-7. [\[http://dx.doi.org/10.1111/j.1600-9657.1999.tb00755.x\]](http://dx.doi.org/10.1111/j.1600-9657.1999.tb00755.x) [PMID: 10379274]
- [16] Kartal N, Özçelik B, Cimilli H. Root canal morphology of maxillary premolars. *J Endod* 1998; 24(6): 417-9. [\[http://dx.doi.org/10.1016/S0099-2399\(98\)80024-1\]](http://dx.doi.org/10.1016/S0099-2399(98)80024-1) [PMID: 9693586]
- [17] Awawdeh L, Abdullah H, Al-Qudah A. Root form and canal morphology of Jordanian maxillary first premolars. *J Endod* 2008; 34(8): 956-61. [\[http://dx.doi.org/10.1016/j.joen.2008.04.013\]](http://dx.doi.org/10.1016/j.joen.2008.04.013) [PMID: 18634927]
- [18] Abella F, Teixidó LM, Patel S, Sosa F, Duran-Sindreu F, Roig M. Cone-beam computed tomography analysis of the root canal morphology of maxillary first and second premolars in a Spanish population. *J Endod* 2015; 41(8): 1241-7. [\[http://dx.doi.org/10.1016/j.joen.2015.03.026\]](http://dx.doi.org/10.1016/j.joen.2015.03.026) [PMID: 25956606]
- [19] Atieh MA. Root and canal morphology of maxillary first premolars in a Saudi population. *J Contemp Dent Pract* 2008; 9(1): 46-53. [\[http://dx.doi.org/10.5005/jcdp-9-1-46\]](http://dx.doi.org/10.5005/jcdp-9-1-46) [PMID: 18176648]
- [20] Alqedairi A, Alfawaz H, Al-Dahman Y, Alnassar F, Al-Jebaly A, Alsubait S. Cone-beam computed tomographic evaluation of root canal morphology of maxillary premolars in a Saudi population. *BioMed Res Int* 2018; 20188170620 [\[http://dx.doi.org/10.1155/2018/8170620\]](http://dx.doi.org/10.1155/2018/8170620) [PMID: 30186867]
- [21] Bürklein S, Heck R, Schäfer E. Evaluation of the root canal anatomy of maxillary and mandibular premolars in a selected German population using cone-beam computed tomographic data. *J Endod* 2017; 43(9): 1448-52. [\[http://dx.doi.org/10.1016/j.joen.2017.03.044\]](http://dx.doi.org/10.1016/j.joen.2017.03.044) [PMID: 28743430]
- [22] Razumova S, Brago A, Khaskhanova L, Howijieh A, Barakat H, Manvelyan A. A cone-beam computed tomography scanning of the root canal system of permanent teeth among the Moscow population. *Int J Dent* 2018; 20182615746 [\[http://dx.doi.org/10.1155/2018/2615746\]](http://dx.doi.org/10.1155/2018/2615746) [PMID: 30356403]
- [23] de Lima CO, de Souza LC, Devito KL, do Prado M, Campos CN. Evaluation of root canal morphology of maxillary premolars: A cone-beam computed tomography study. *Aust Endod J* 2019; 45(2): 196-201. [\[http://dx.doi.org/10.1111/aej.12308\]](http://dx.doi.org/10.1111/aej.12308) [PMID: 30230115]
- [24] Sadaf A, Huma Z, Javed S, Masood A. Maxillary Premolar teeth: Root and canal stereoscopy. *KMUJ* 2019; 11(4): 240-7.
- [25] Tian YY, Guo B, Zhang R, *et al.* Root and canal morphology of maxillary first premolars in a Chinese subpopulation evaluated using cone-beam computed tomography. *Int Endod J* 2012; 45(11): 996-1003. [\[http://dx.doi.org/10.1111/j.1365-2591.2012.02059.x\]](http://dx.doi.org/10.1111/j.1365-2591.2012.02059.x) [PMID: 22551454]
- [26] Fan L, Yuan K, Niu C, Ma R, Huang Z. A cone-beam computed tomography study of the mesial cervical concavity of maxillary first premolars. *Arch Oral Biol* 2018; 92: 79-82. [\[http://dx.doi.org/10.1016/j.archoralbio.2018.05.002\]](http://dx.doi.org/10.1016/j.archoralbio.2018.05.002) [PMID: 29775860]
- [27] Neelakantan P, Subbarao C, Ahuja R, Subbarao CV. Root and canal morphology of Indian maxillary premolars by a modified root canal staining technique. *Odontology* 2011; 99(1): 18-21. [\[http://dx.doi.org/10.1007/s10266-010-0137-0\]](http://dx.doi.org/10.1007/s10266-010-0137-0) [PMID: 21271321]
- [28] Gupta S, Sinha DJ, Gowhar O, Tyagi SP, Singh NN, Gupta S. Root and canal morphology of maxillary first premolar teeth in north Indian population using clearing technique: An *in vitro* study. *J Conserv Dent* 2015; 18(3): 232-6. [\[http://dx.doi.org/10.4103/0972-0707.157260\]](http://dx.doi.org/10.4103/0972-0707.157260) [PMID: 26069411]
- [29] Ahmed HMA, Cheung GS. Accessory roots and root canals in maxillary premolar teeth: A review of a critical endodontic challenge. *Endo* 2012; 6(1): 7-18.
- [30] Ozcan E, C € , olak H, Hamidi MM. Root and canal morphology of maxillary first premolars in a Turkish population. *JDS* 2012; 7(4): 390-4.
- [31] Ahmad IA, Alenezi MA. Root and root canal morphology of maxillary first premolars: A literature review and clinical considerations. *J Endod* 2016; 42(6): 861-72. [\[http://dx.doi.org/10.1016/j.joen.2016.02.017\]](http://dx.doi.org/10.1016/j.joen.2016.02.017) [PMID: 27106718]
- [32] Bulut DG, Kose E, Ozcan G, Sekerci AE, Canger EM, Sisman Y. Evaluation of root morphology and root canal configuration of premolars in the Turkish individuals using cone beam computed tomography. *Eur J Dent* 2015; 9(4): 551-7. [\[http://dx.doi.org/10.4103/1305-7456.172624\]](http://dx.doi.org/10.4103/1305-7456.172624) [PMID: 26929695]
- [33] Green D. Double canals in single roots. *Oral Surg Oral Med Oral Pathol* 1973; 35(5): 689-96. [\[http://dx.doi.org/10.1016/0030-4220\(73\)90037-6\]](http://dx.doi.org/10.1016/0030-4220(73)90037-6) [PMID: 4512513]
- [34] Peiris R, Takahashi M, Sasaki K, Kanazawa E. Root and canal morphology of permanent mandibular molars in a Sri Lankan population. *Odontology* 2007; 95(1): 16-23. [\[http://dx.doi.org/10.1007/s10266-007-0074-8\]](http://dx.doi.org/10.1007/s10266-007-0074-8) [PMID: 17660977]
- [35] Ok E, Altunsoy M, Nur BG, Aglarci OS, Çolak M, Güngör E. A cone-beam computed tomography study of root canal morphology of maxillary and mandibular premolars in a Turkish population. *Acta Odontol Scand* 2014; 72(8): 701-6. [\[http://dx.doi.org/10.3109/00016357.2014.898091\]](http://dx.doi.org/10.3109/00016357.2014.898091) [PMID: 24832561]
- [36] Saber SEDM, Ahmed MHM, Obeid M, Ahmed HMA. Root and canal morphology of maxillary premolar teeth in an Egyptian subpopulation using two classification systems: A cone beam computed tomography study. *Int Endod J* 2019; 52(3): 267-78. [\[http://dx.doi.org/10.1111/iej.13016\]](http://dx.doi.org/10.1111/iej.13016) [PMID: 30225932]
- [37] Yang L, Chen X, Tian C, Han T, Wang Y. Use of cone-beam computed tomography to evaluate root canal morphology and locate root canal orifices of maxillary second premolars in a Chinese subpopulation. *J Endod* 2014; 40(5): 630-4. [\[http://dx.doi.org/10.1016/j.joen.2014.01.007\]](http://dx.doi.org/10.1016/j.joen.2014.01.007) [PMID: 24767555]
- [38] Al-Ghananeem MM, Haddadin K, Al-Khreisat AS, Al-Weshah M, Al-Hababeh N. The number of roots and canals in the maxillary second premolars in a group of Jordanian population. *Int J Dent* 2014; 2014797692 [\[http://dx.doi.org/10.1155/2014/797692\]](http://dx.doi.org/10.1155/2014/797692) [PMID: 25530761]
- [39] Li YH, Bao SJ, Yang XW, Tian XM, Wei B, Zheng YL. Symmetry of root anatomy and root canal morphology in maxillary premolars analyzed using cone-beam computed tomography. *Arch Oral Biol* 2018; 94: 84-92. [\[http://dx.doi.org/10.1016/j.archoralbio.2018.06.020\]](http://dx.doi.org/10.1016/j.archoralbio.2018.06.020) [PMID: 29990589]
- [40] Elnour M, Khabeer A, AlShwaimi E. Evaluation of root canal morphology of maxillary second premolars in a Saudi Arabian subpopulation: An *in vitro* microcomputed tomography study. *Saudi Dent J* 2016; 28(4): 162-8. [\[http://dx.doi.org/10.1016/j.sdentj.2016.08.001\]](http://dx.doi.org/10.1016/j.sdentj.2016.08.001) [PMID: 27872546]
- [41] Felsypemila G, Vinothkumar TS, Kandaswamy D. Anatomic symmetry of root and root canal morphology of posterior teeth in Indian subpopulation using cone beam computed tomography: A retrospective study. *Eur J Dent* 2015; 9(4): 500-7. [\[http://dx.doi.org/10.4103/1305-7456.172623\]](http://dx.doi.org/10.4103/1305-7456.172623) [PMID: 26929687]
- [42] Johnsen GF, Dara S, Asjad S, Sunde PT, Haugen HJ. Anatomic comparison of contralateral premolars. *J Endod* 2017; 43(6): 956-63. [\[http://dx.doi.org/10.1016/j.joen.2017.01.012\]](http://dx.doi.org/10.1016/j.joen.2017.01.012) [PMID: 28377148]
- [43] Xu J, Shao MY, Pan HY, *et al.* A proposal for using contralateral teeth to provide well-balanced experimental groups for endodontic studies. *Int Endod J* 2016; 49(10): 1001-8. [\[http://dx.doi.org/10.1111/iej.12553\]](http://dx.doi.org/10.1111/iej.12553) [PMID: 26383870]
- [44] Martins JNR, Marques D, Francisco H, Caramés J. Gender influence on the number of roots and root canal system configuration in human permanent teeth of a Portuguese subpopulation. *Quintessence Int* 2018; 49(2): 103-11. [PMID: 29234740]
- [45] Ahmed HMA, Dummer PMH. A new system for classifying tooth, root and canal anomalies. *Int Endod J* 2018; 51(4): 389-404. [\[http://dx.doi.org/10.1111/iej.12867\]](http://dx.doi.org/10.1111/iej.12867) [PMID: 29023779]
- [46] Leoni GB, Versiani MA, Pécora JD, Damião de Sousa-Neto M. Micro-computed tomographic analysis of the root canal morphology of mandibular incisors. *J Endod* 2014; 40(5): 710-6. [\[http://dx.doi.org/10.1016/j.joen.2013.09.003\]](http://dx.doi.org/10.1016/j.joen.2013.09.003) [PMID: 24767569]
- [47] Ahmed HMA, Rossi-Fedele G. Preferred reporting items for root and canal anatomy in the human dentition (PROUD 2020) - A systematic review and a proposal for a standardized protocol. *Eur Endod J* 2020; 5(3): 159-76. [PMID: 33353923]