



The Open Dentistry Journal

Content list available at: <https://opendentistryjournal.com>



RESEARCH ARTICLE

Use of 3D Imaging for Treatment Planning in Cases of Impacted Canines

Marco Portelli^{1*}, Riccardo Nucera¹, Rosamaria Fastuca¹, Marco Cicciù¹, Antonino Lo Giudice¹ and Angela Militi¹

¹Department of Biomedical, Dental Science and Morphological and Functional Images, Dental School, University of Messina, Messina, Italy

Abstract:

Background:

The use of 3D imaging offers the possibility to improve diagnosis and treatment planning in several fields of dental science.

Objective:

The aim of this study is to evaluate the usefulness of 3D evaluation for surgical exposure treatment planning in cases of impacted canine.

Methods:

This retrospective study has been conducted on the clinical reports of twenty patients (11 F - 9 M) with a mean age of 15.4 years, affected by the impacted canine. Each patient underwent a CBCT exam (Hitachi MercuRay, Hitachi Medical Technology, Tokyo, Japan), in order to obtain sagittal, axial and coronal images and a 3D surface rendering. The images have been evaluated by 14 experts orthodontists who were divided into two groups. The first group first evaluates the bidimensional images and then the 3D images and the second group instead has done exactly the opposite. Each orthodontist has elaborated a treatment plan for the impacted canine correction with a specific indication about surgical exposure approach (Palatal-Vestibular) and orthodontic biomechanics.

Results:

The level of concordance in treatment planning of the 3D images evaluation and the bidimensional images was found to be greater in the second group of orthodontists. Moreover, in this group, the time spent for the treatment plan has been lower than in the first group (12 ± 3.32 min vs. 23 ± 2.53 min, $p < 0.05$).

Conclusion:

According to the results of the present study, it is possible to state that CBTC is fundamental for the diagnosis and treatment planning of impacted canine. However, further studies are necessary to confirm the greater reliability of 3D surface rendering compared to the bidimensional images.

Keywords: Alveolar bone remodeling, Bidimensional imaging, Cone beam technology, Dental anomalies, Impacted canine, 3D rendering.

Article History

Received: November 27, 2018

Revised: February 26, 2019

Accepted: March 19, 2019

1. INTRODUCTION

Permanent teeth eruption represents the final step of a complex series of events controlled by genetic and epigenetic patterns. In most cases, tooth bud, after coronal development, erupts in oral cavity reaching the occlusal plane. At this point, the dental element is affected by occlusal and masticatory stresses, therefore active eruption breaks. Dental eruption is related to both root development and alveolar bone remodeling.

In the beginning, it is necessary that permanent teeth go along the physiologic way of the eruption, reabsorbing the root of the deciduous tooth. However, several local or systemic factors can get in the way of permanent teeth eruption producing dental impaction [1]. The genetic component of tooth impaction can be investigated by evaluating the associated dental anomalies. The impacted teeth can be in fact associated to other dental anomalies and in particular with tooth transposition and supernumerary tooth [2].

This clinical eventuality produces in the absence of one or more teeth over the physiologic period. It is necessary to distinguish dental impaction and dental retention. In this last case, even if the tooth has not erupted within the physiologic

* Address correspondence to this author at the Department of Biomedical, Dental Science and Morphological and Functional Images Dental School, Faculty of Medicine, University of Messina, Via Consolare Valeria, Gazzi, C.A.P. 98100 Messina, Italy; Tel: 0039090/2216910; Fax 0039090/2216911; E-mail: mportelli@unime.it

time, the root is yet to be developed. So a delayed eruption can be expected. Dental impaction may affect one or more teeth, deciduous or permanent, and can be endosseous or sub-mucosus. In this last case, it is possible to distinguish a total or a partial inclusion, depending on the presence of a complete or a partial mucosus coating of the dental element. Epidemiological studies reported a mean incidence of dental impaction equal to 20% in developed populations, especially in the European one with prevalence in the female sex. The most affected tooth is the mandibular third molar followed by the maxillary third molar and the maxillary canine. Canine bilateral impaction occurs only in 8-10% of cases. Even if the development of canine germ occurs in a vestibular position in the adjacent teeth, canine impaction is palatal in 75% of cases. The agenesis of a permanent canine is extremely rare in non-syndromic patients. In cases of syndromic canine agenesis, instead, early detection of the associated medical conditions is extremely important [3]. The therapeutic approach to canine impaction is multidisciplinary and involves several specialists such as an orthodontist, oral surgeon and periodontologist. Treatment planning is based on several items such as the position of the canine, the surgical accessibility and the prognosis of the intervention, both on the impacted tooth and on the adjacent teeth [4]. Treatment planning is carried out on the basis of bidimensional [5] and three dimensional [6 - 8] radiological investigations. The new frontier in dental imaging is represented by Cone Beam Technology. The use of 3D imaging gave the possibility to improve diagnosis and treatment planning in several fields of dental science [9 - 11].

The aim of this study is to evaluate the usefulness of 3D virtual imaging of dental elements for the treatment planning in cases of impacted canine [12, 13].

2. MATERIALS AND METHODS

This retrospective study has been performed on the clinical reports of twenty patients (11 F, 9 M), afferent to the Department of Orthodontics at the University of Messina, from March 2015 to May 2018, and affected by maxillary cuspid inclusion. For each patient, informed consent has been acquired for the treatment through an apposite validated model. In the study group, 29 impacted canine has been recorded in total, in 9 bilateral cases. The age of the patients selected was between 12, 8 and 26, 8 ages (mean 15, 4 \pm 2.4). Exclusion criteria were: Dental anomalies, craniofacial deformities, incomplete root development and previous orthodontic treatments. The canine impaction diagnosis has been made on the basis of clinical evidence that permanent cuspid has not erupted beyond the physiological period and through a radiological examination. The orthodontic check-up was carried out for the patients, comprehended intra and extra-oral photos, Orthopano-ramic X-Ray and impressions in alginate of both the arches in order to obtain dental casts. After the diagnosis of impacted canine, each patient underwent a CBCT exam (Hitachi MercuRay, Hitachi Medical Technology, Tokyo, Japan), in order to obtain:

- Sagittal (Fig. 1), Coronal (Fig. 2) and Axial (Fig. 3) images
- 3D Surface Rendering (Fig. 4)

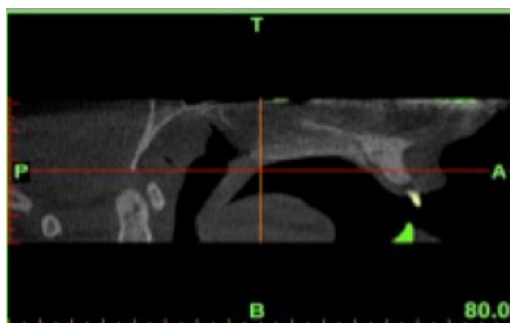


Fig. (1). Sagittal.

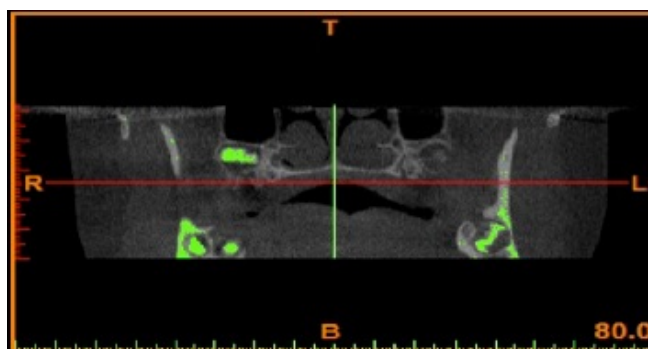


Fig. (2). Coronal.

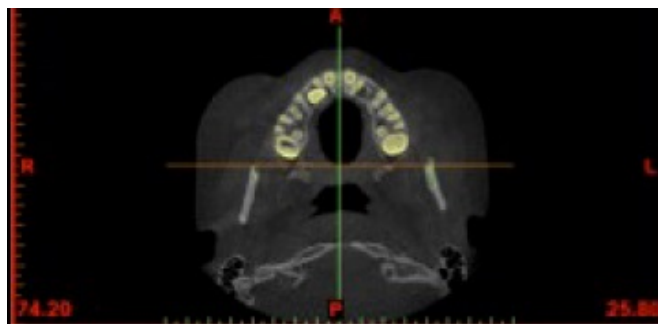


Fig. (3). Axial.

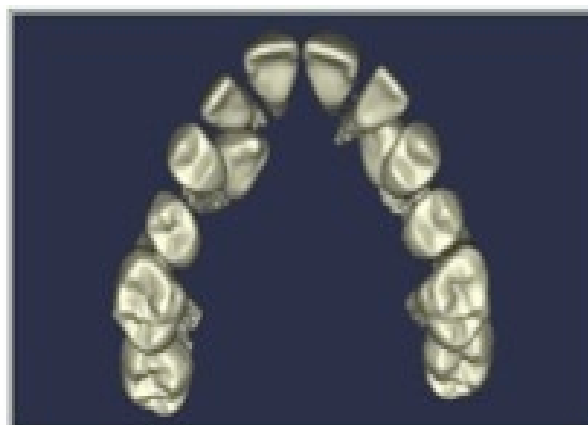
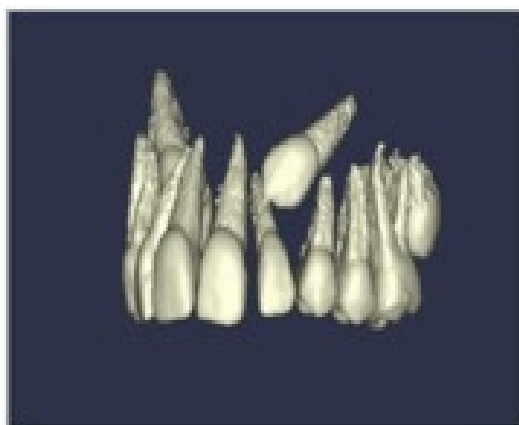


Fig. (4). 3D Surface Rendering.

Both 2D and 3D images have been obtained in files DICOM and CBWorks software (CyberMed, Seoul, Korea) has been used for segmentation procedure. Subsequently, due to the subtraction techniques, hard and soft tissues maintaining only maxillary teeth have been removed. In order to avoid possible bias related to the operator, only one expert operator performed maxillary teeth segmentation. 3D images of impacted cuspids have been evaluated on the sagittal, frontal and axial planes. Impacted canines images have been selected by an independent operator that used a randomization system (www.randomizer.org). Image analysis has been performed by 14 expert orthodontists' which implemented a treatment planning of four maxillary impacted canines of similar clinical complexity. Each orthodontist provide a specific form in order to acquire personal data of the patient and elaborate a treatment plan for the correction of canine impaction with a specific indication about surgical approach (Palatal-Vestibular) and orthodontic biomechanics. The study group has been divided into two subgroups:

- GROUP 1 → Consisting of seven orthodontists that have been evaluated at first the bi-dimensional images (V1) and then the 3D rendering (V2)
- GROUP 2 → Consisting of seven orthodontists that have been evaluated at first the 3D rendering images (V1) and then the bi-dimensional ones (V2)

Evaluation form filled out by the orthodontist both at V1 and at V2, requires:

- [1] Mesiodistal position of the canine
- [2] Vestibular-palatal position of the canine
- [3] Vertical position of the canine
- [4] Root resorption
- [5] Treatment plan with extractions
- [6] Treatment plan without extractions
- [7] Orthodontic approach (Vestibular or Palatal)
- [8] Direction of initial orthodontic traction vector (Vestibular-Palatal or Mesiodistal)
- [9] Direction of secondary orthodontic traction vector (Vestibular-Palatal or Mesiodistal)
- [10] Possibility of spontaneous eruption
- [11] Level of root development and spontaneous eruption
- [12] Possible root resorption of the adjacent teeth
- [13] Need more diagnostic investigations

For both sub-group study, if the evaluations at V1 and V2 were concordant, a score of 1 was assigned if it was not concordant, a score of 0 was attributed. The time necessary for each clinician to perform the treatment plan at V1 has been evaluated. All the teeth have been evaluated in a single session. The assignment of the orthodontist to the two subgroups has been carried out with a randomization system (www.randomizer.org). The time necessary to complete the validated form used in the study ranged between 1,5 and 2,5 hours.

2.1. Power Analysis of the Sample and Statistical Analysis

In order to evaluate the correct number of patients to enroll in the present study, a power test has been carried out on a

preliminary enrolled small sample. The sample size calculation was performed considering the following outcome: Mesiodistal canine position. The calculation was executed considering the following data: Group 1 (17% of concordance) and group 2 (75% of concordance). The power analysis calculation was performed placing $1-\beta$ at 0.8 and Alfa at 0.05. Median value and standard deviation of the parameter T have been calculated for both group, and they were compared with a T-Student Test. A count of the scores 0 and 1 inside the two study subgroups has been performed and then has been compared with a T-Student Test. The level of significance was with $\alpha < 0.05$. Data has been analyzed with StatView (version 5, SAS Institute, Cary, NC) in order to evaluate the difference between bi-dimensional images and 3D renderings.

3. RESULTS

All orthodontist completed the survey and the observation, and used it for this study. The analysis of the survey filled out in two subgroups at V1 and V2 revealed a difference in the mesiodistal position of the impacted canines with a level of discordance equal to 75% ($p > 0.05$). This finding was higher for the vestibular-palatal position evaluation with a level of discordance equal to 84% ($p > 0.05$). Regarding the vertical position of the canine, the concordance was in the 50% of cases; for root resorption instead, the concordance was at a level of 44%. In this case, image quality (2D vs 3D) had significantly influenced the evaluation ($p < 0.0001$). The significant discrepancy was found in treatment planning, including the possibility of repositioning or extraction, and in cases of tooth recovery, about the choice of initial vector. In 27% of cases, treatment planning has been modified after 3D

rendering images observation, and also the choice of initial recovery vector has been corrected. In Group 2 study, when 3D rendering images have been observed before the bidimensional ones, the level of concordance between the evaluation at V1 and V2 was significantly higher than in Group 1 study. In this group, ten score concordance modifications between V1 and V2 have been registered, instead in the Group 2 study, only four changes have been made. The variables of agreement to the survey form in the two study groups have been graphically reported in Fig. (5).

A significant difference has been registered about the time necessary to perform treatment planning; in the Group 2 study, the meantime registered was lower than in group 1 study (12 ± 3.32 min vs 23 ± 2.53 min, $p < 0.05$).

4.. DISCUSSION

In this study, the clinical relevance of 3D CBCT images compared to the 2D ones has been evaluated for the diagnosis and treatment planning of impacted canines. CBCT allows 3D reconstruction on craniomaxillofacial district and provides the dynamic images. Unlike, conventional radiology produces only a static planar image [14 - 16]. CBCT images can be formatted in order to obtain traditional radiographic projection such as ortopano, latero-lateral and postero-anterior projections. CBCT prefers traditional Computed Tomography for the lower costs and the reduced radiological exposition [17 - 21]. The results of the present study show difference, although not all significant, between the two study groups for the observations performed at V1 and V2, above all for the vestibular-paltal and mesiodistal position of the impacted teeth.

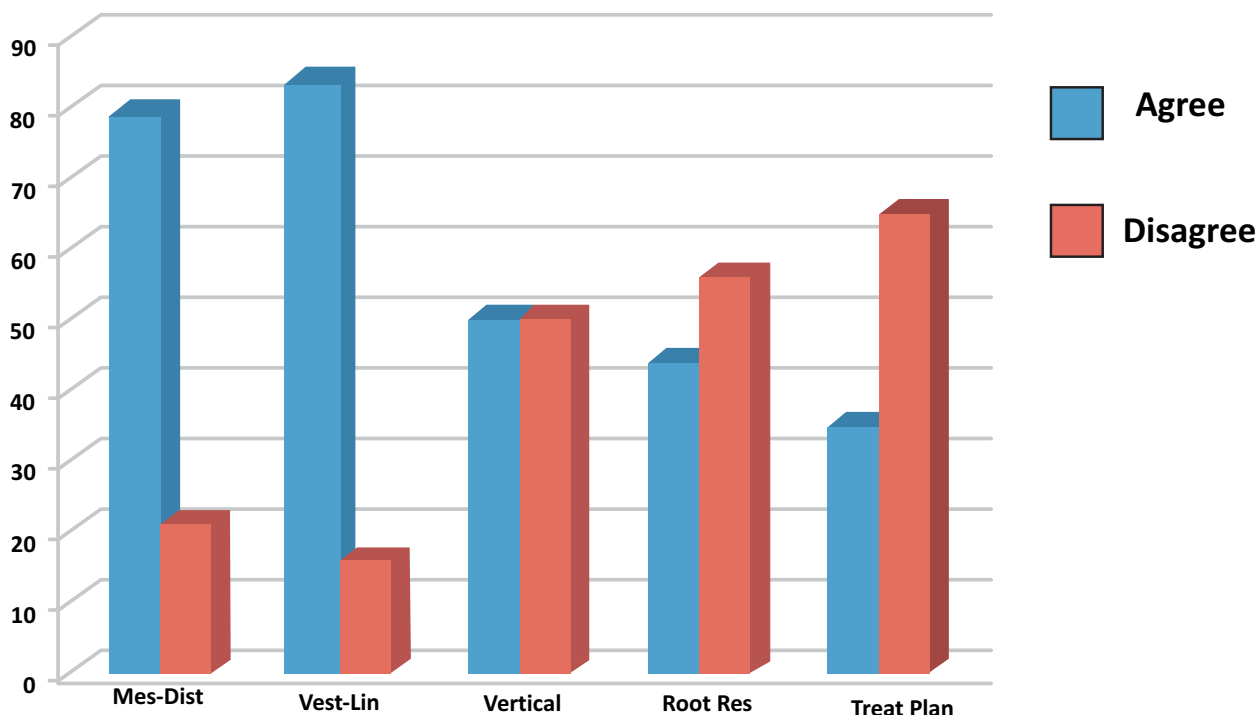


Fig. (5). Variables of agreement to the survey form.

A significant difference has been registered for treatment planning. In 27% of cases, treatment planning has been modified after 3D surface rendering observation because 3D images provide more direct information than 2D CBCT images [22]. In cases of root resorption of adjacent teeth, 3D surface rendering is however affected by operator subjectivity. The limits of the present study are:

- Clinicians evaluated the same level of complexity cases; results may be different in cases of different clinical complexity
- Operators' enrolled in the study was expected orthodontist; clinical experience may affect the results of the observations

3D images allow clinicians to better distinguish cases of superficial impaction that can be easily exposed using LASER technique producing less trauma to the patients [23] and allowing more rapid and painless healing of tissues. Results of the present study demonstrate that CBCT is fundamental for the diagnosis and treatment planning of canine impaction. However, further studies are necessary to confirm the greater reliability of 3D surface rendering compared to bi-dimensional images, also considering higher radiological exposition.

CONCLUSION

Within the limitations of the present study, according to the results obtained by the authors, it was concluded that:

- CBCT 3D rendering images are more reliable and clinically relevant with respect to 2D images; 3D CBCT images may affect significantly orthodontic treatment planning in complex clinical cases such as impacted canines [24].
- CBCT provides high-quality images, that allow clinicians to evaluate the position of an impacted tooth with a high degree of accuracy, allowing at the same time a more conservative surgical procedure, [25] if necessary.
- CBCT allows an extremely accurate orthodontic biomechanics planning in cases of impacted teeth [26, 27], avoiding, therefore, the risk of an incongruous use of orthodontic force vectors or root resorptions.

ETHICS APPROVAL AND CONSENT TO PARTICIPATE

This retrospective study involved human subjects, but patients followed a traditional diagnostic protocol; no supplementary investigations has been done only for scientific reasons. The radiological examination was conducted in the respect of the ALARA Principle, so an Ethical approval was not necessary.

HUMAN AND ANIMAL RIGHTS

No animals were used for studies that are the basis of this research. All research procedures followed were in accordance with the Helsinki Declaration of 1975, as revised in 2013.

CONSENT FOR PUBLICATION

Written informed consent for the participation was obtained from each participant.

CONFLICT OF INTEREST

The authors declare no conflict of interest, financial or otherwise.

ACKNOWLEDGEMENTS

Declared none.

REFERENCES

- [1] Militi D, Militi A, Cutrupi MC, *et al.* Genetic basis of non syndromic hypodontia: A DNA investigation performed on three couples of monozygotic twins about PAX9 mutation. *Eur J Paediatr Dent* 2011; 12(1): 21-4. [PMID: 21434731]
- [2] Laganà G, Venza N, Borzabadi-Farahani A, Fabi F, Danesi C, Cozza P. Dental anomalies: Prevalence and associations between them in a large sample of non-orthodontic subjects: A cross-sectional study. *BMC Oral Health* 2017; 17(1): 62. [http://dx.doi.org/10.1186/s12903-017-0352-y] [PMID: 28284207]
- [3] Borzabadi-Farahani A. Bilateral agenesis of maxillary permanent canines: Review of the literature. *J Orthod Sci* 2015; 4(1): 26-9. [http://dx.doi.org/10.4103/2278-0203.149614] [PMID: 25657989]
- [4] Yan B, Sun Z, Fields H, Wang L. Maxillary canine impaction increases root resorption risk of adjacent teeth: A problem of physical proximity. *Am J Orthod Dentofacial Orthop* 2012; 142(6): 750-7. [http://dx.doi.org/10.1016/j.ajodo.2012.07.016] [PMID: 23195360]
- [5] Sajjani AK, King NM. Early prediction of maxillary canine impaction from panoramic radiographs. *Am J Orthod Dentofacial Orthop* 2012; 142(1): 45-51. [http://dx.doi.org/10.1016/j.ajodo.2012.02.021] [PMID: 22748989]
- [6] Alqerban A, Hedesiu M, Baciut M, *et al.* Pre-surgical treatment planning of maxillary canine impactions using panoramic vs cone beam CT imaging. *Dentomaxillofac Radiol* 2013; 42(9): 20130157. [http://dx.doi.org/10.1259/dmfr.20130157] [PMID: 23906975]
- [7] Portelli M, Militi A, Lo Giudice A, *et al.* Standard and low-dose cone beam computer tomography protocol for orthognatodontic diagnosis: A comparative evaluation. *J Biol Regul Homeost Agents* 2018; 32(2)(Suppl. 2): 59-66. [PMID: 29720332]
- [8] Bedoya MM, Park JH. A review of the diagnosis and management of impacted maxillary canines. *J Am Dent Assoc* 2009; 140(12): 1485-93. [http://dx.doi.org/10.14219/jada.archive.2009.0099] [PMID: 19955066]
- [9] Lucchese A, Portelli M, Marcolina M, *et al.* Effect of dental care on the oral health of Sjögren's syndrome patients. *J Biol Regul Homeost Agents* 2018; 32(2)(Suppl. 2): 37-43. [PMID: 29720329]
- [10] Traini T, Danza M, Zollino I, *et al.* Histomorphometric evaluation of an immediately loaded implant retrieved from human mandible after 2 years. *Int J Immunopathol Pharmacol* 2011; 24(2)(Suppl.): 31-6. [http://dx.doi.org/10.1177/03946320110240S207] [PMID: 21781443]
- [11] Lucchese A, Manuelli M. Prognosis of third molar eruption: A comparison of three predictive methods. *Prog Orthod* 2003; 4(2): 4-19. [PMID: 14985794]
- [12] Becker A. In defense of the guidance theory of palatal canine displacement. *Angle Orthod* 1995; 65(2): 95-8. [PMID: 7785811]
- [13] Bedoya MM, Park JH. A review of the diagnosis and management of impacted maxillary canines. *J Am Dent Assoc* 2009; 140(12): 1485-93. [http://dx.doi.org/10.14219/jada.archive.2009.0099] [PMID: 19955066]
- [14] Yan B, Sun Z, Fields H, Wang L, Luo L. Etiologic factors for buccal and palatal maxillary canine impaction: A perspective based on cone-beam computed tomography analyses. *Am J Orthod Dentofacial Orthop* 2013; 143(4): 527-34. [http://dx.doi.org/10.1016/j.ajodo.2012.11.021] [PMID: 23561415]
- [15] Katheria BC, Kau CH, Tate R, Chen JW, English J, Bouquot J.

- Effectiveness of impacted and supernumerary tooth diagnosis from traditional radiography *versus* cone beam computed tomography. *Pediatr Dent* 2010; 32(4): 304-9. [PMID: 20836949]
- [16] Larson BE. Cone-beam computed tomography is the imaging technique of choice for comprehensive orthodontic assessment. *Am J Orthod Dentofacial Orthop* 2012; 141(4): 402-411, 404, 406 passim. [http://dx.doi.org/10.1016/j.ajodo.2012.02.009] [PMID: 22464520]
- [17] Chau AC, Fung K. Comparison of radiation dose for implant imaging using conventional spiral tomography, computed tomography, and cone-beam computed tomography. *Oral Surg Oral Med Oral Pathol Oral Radiol Endod* 2009; 107(4): 559-65. [http://dx.doi.org/10.1016/j.tripleo.2008.11.009] [PMID: 19168378]
- [18] Al Najjar A, Colosi D, Dauer LT, *et al.* Comparison of adult and child radiation equivalent doses from 2 dental cone-beam computed tomography units. *Am J Orthod Dentofacial Orthop* 2013; 143(6): 784-92. [http://dx.doi.org/10.1016/j.ajodo.2013.01.013] [PMID: 23726328]
- [19] Lorenzoni DC, Bolognese AM, Garib DG, Guedes FR, Sant'anna EF. Cone-beam computed tomography and radiographs in dentistry: Aspects related to radiation dose. *Int J Dent* 2012; 2012(18): 813768. [PMID: 22548064]
- [20] Larson BE. Cone-beam computed tomography is the imaging technique of choice for comprehensive orthodontic assessment. *Am J Orthod Dentofacial Orthop* 2012; 141(4): 402-411, 404, 406 passim. [http://dx.doi.org/10.1016/j.ajodo.2012.02.009] [PMID: 22464520]
- [21] Caprioglio A, Siani L, Caprioglio C. Guided eruption of palatally impacted canines through combined use of 3-dimensional computerized tomography scans and the easy cuspid device. *World J Orthod* 2007; 8(2): 109-21. [PMID: 17580504]
- [22] Kau CH, Richmond S, Eds. Three-dimensional imaging for Orthodontics and maxillofacial surgery. *General dentistry*. Wiley Blackwell 2010; p. 320.
- [23] Borzabadi-Farahani A, Cronshaw M. Lasers in orthodontics. In: Coluzzi D, Parker S, Eds. *Lasers in Dentistry-Current Concepts*. Textbooks in Contemporary Dentistry. Springer, Cham 2017; pp. 247-71.
- [24] Haney E, Gansky SA, Lee JS, *et al.* Comparative analysis of traditional radiographs and cone-beam computed tomography volumetric images in the diagnosis and treatment planning of maxillary impacted canines. *Am J Orthod Dentofacial Orthop* 2010; 137(5): 590-7. [http://dx.doi.org/10.1016/j.ajodo.2008.06.035] [PMID: 20451777]
- [25] Walker L, Enciso R, Mah J. Three-dimensional localization of maxillary canines with cone-beam computed tomography. *Am J Orthod Dentofacial Orthop* 2005; 128(4): 418-23. [http://dx.doi.org/10.1016/j.ajodo.2004.04.033] [PMID: 16214621]
- [26] Pair J. Transposition of a maxillary canine and a lateral incisor and use of cone-beam computed tomography for treatment planning. *Am J Orthod Dentofacial Orthop* 2011; 139(6): 834-44. [http://dx.doi.org/10.1016/j.ajodo.2009.08.035] [PMID: 21640891]
- [27] Lucchese A, Sfondrini MF, Manuelli M, Gangale S. Fixed space maintainer for use with a rapid palatal expander. *J Clin Orthod* 2005; 39(9): 557-8. [PMID: 16244419]